

Tubularized Incised-Plate (TIP) Repair Augmented by Spongioplasty for Distal and Midpenile Hypospadias

Wael Mohamed Gamal, Mohamed Zaki, Ahmed Rashid, Mohamed Mostafa, Abd El Monem Abouzeid

Sohag University Hospital, Sohag, Egypt

Submitted March 25, 2009 - Accepted for Publication April 21, 2009

ABSTRACT

INTRODUCTION: The objective of the study was to evaluate the cosmetic and functional results of tubularized incised-plate (TIP) repair of distal and midpenile hypospadias, using the hemicorpora spongiosa as an additional cover in the Y to I maneuver.

METHODS: From February 2004 to February 2007, 50 patients with distal (n=30) and midpenile (n=20) hypospadias had surgical repair. The mean age of the patients was 4.2 years (range, 2-6 years). All patients received primary TIP repair with bilateral dissection of the hemicorpora spongiosa to cover the neourethra (spongioplasty).

RESULTS: The mean follow-up period was 12.6 months (range, 10-17 months). Of the 50 cases, 48 patients (96%) had successful outcome with regard to a straight urine stream, vertically slit meatus, and acceptable cosmetic appearance. Two patients with midpenile hypospadias developed a small fistula at the site of the native meatus. Both patients had successful fistula closure through a secondary repair 3 months later.

CONCLUSION: Spongioplasty is a reliable and important adjunct for covering the neourethra in TIP hypospadias repair. This surgical technique results in a low rate of fistula formation.

KEYWORDS: Hypospadias; Spongioplasty; Urethra.

CORRESPONDENCE: Wael M Gamal, MD, Department of Urology, Sohag University, 31 el nasr Street, Sohag, Egypt (wael_saad_el_dien@hotmail.com).

INTRODUCTION

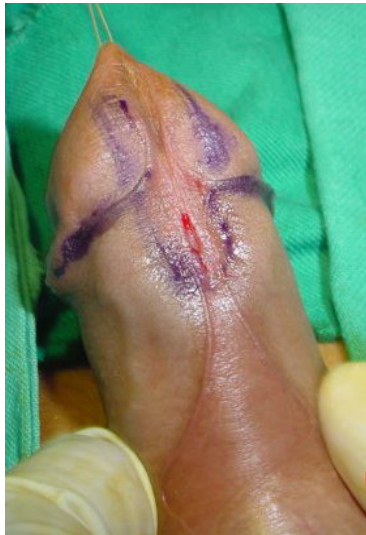In the last 20 years major advances in instrumentation, suture materials, and anatomical and histological understanding have evoked an exponential number of new and modified techniques for the correction of hypospadias. These surgical advances have enabled the urologists to correct most cases of hypospadias with excellent functional and cosmetic results [1].

The Snodgrass technique is the procedure of choice for distal and midpenile hypospadias because it is versatile and easy to

perform. It also has good cosmetic outcome with a vertically-orientated meatus that is similar to a normal circumcised penis [3]. However, despite obvious surgical advances in hypospadias repair, no single technique has been developed that is completely without complications. The most common and particularly annoying complication is urethrocutaneous fistula [2,4].

Several procedures have been described for preventing fistula formation [5]. The purpose of the present investigation was to evaluate the results of tubularized incised-plate (TIP) repair

Figure 1. Two Parallel Longitudinal Marks Around the Urethral Plate (Arrows Show Well-Formed Spongial Tissue). doi: 10.3834/uij.1944-5784.2009.06.13f1



of distal and midpenile hypospadias, using the hemicorpora spongiosa as an additional cover in the Y to I maneuver.

METHODS

Participants

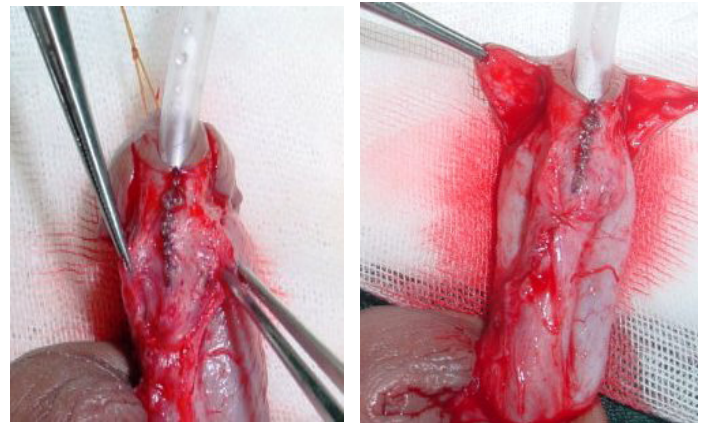
The participants were 50 children with well-developed spongial tissue (those with underdeveloped spongial tissue were excluded from this study). Their mean age was 4.2 years (range, 2-6 years). The hypospadiac meatus was distal in 30 children (60%) and midshaft in 20 (40%). None of the patients had associated congenital anomalies or needed preoperative hormonal therapy.

Procedure

All children received primary hypospadias repair using standard primary TIP urethroplasty, in conjunction with spongiosal tissue covering of the neourethra to prevent the occurrence of urethrocutaneous fistula. The operation was done under general anesthesia without the use of tourniquet.

After draping the patient from the umbilicus to the upper part of the thigh, the penis was placed on tension with a glans traction suture and the dorsal hood was lysed from the glans head. The urethral meatus was calibrated and the integrity, thickness, and width of the urethral plate and skin were assessed. Mucosal collar traction sutures were placed on

Figure 2. Neourethra Formation and Dissection of the Hemicorpora Spongiosa. doi: 10.3834/uij.1944-5784.2009.06.13f2



the ventrolateral inner prepuce, as described by Firlit [6]. The collars were distracted laterally to tent the ventral skin at the level of the native meatus. A micro-knife was used to make an incision from tip to tip from each marking suture of the mucosal collars. The incision in the midline was adjusted to skirt around the native urethral meatus. Extreme care was taken to incise only through the dermis on top of the distal urethra (Figure 1).

Orthoplasty was performed by dorsal tunica albuginea placcation, if needed. Two parallel longitudinal incisions separated the urethral plate from the glans wings. The urethral plate was then incised in the midline from the hypospadiac meatus to the area just proximal to the glans tip. The urethral plate was then

Figure 3. Approximation of the Hemicorpora to Cover the Neourethra (Y into I Maneuver). doi: 10.3834/uij.1944-5784.2009.06.13f3

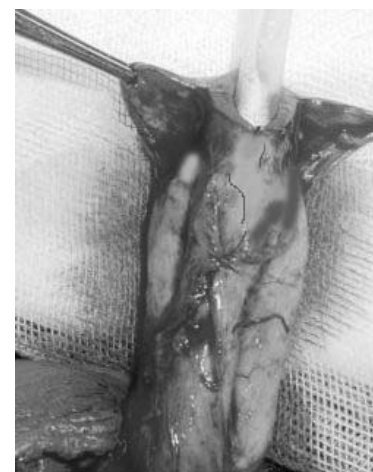
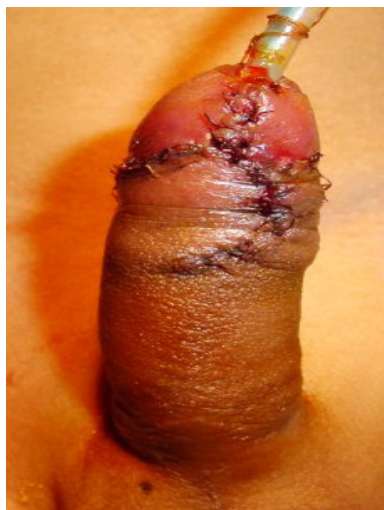
Figure 4. Skin Coverage Following Spongioplasty.

doi: 10.3834/uj.1944-5784.2009.06.13f4



tubularized over a suitable silicone stent using 6/0 polyglactin sutures. The spongial tissue was dissected from the underlying tunica albuginea on its lateral edges deep enough to be closed without tension (Figure 2). Then, medial approximation of the two dissected hemicorpora spongiosa created a covering layer over the TIP urethroplasty (Figure 3).

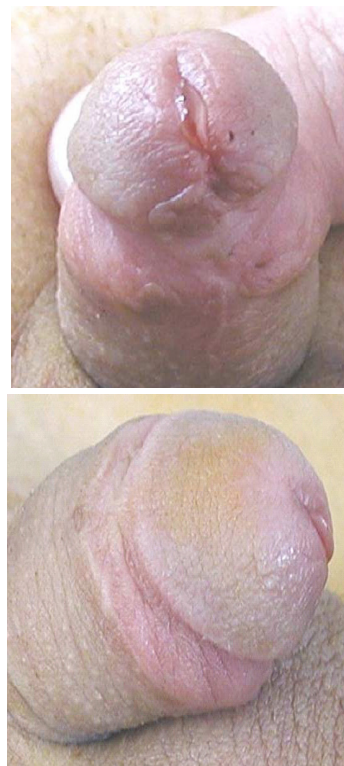The glans wings were approximated with no tension and closed with 6/0 monofilament sutures in two layers. The remainder of the penile skin shaft was closed in one layer as in Figure 4. A urethral stent was secured to the glans with 5/0 polypropylene sutures for 5 days in all cases. A dressing was applied around the penis in the stretched position. Oral antibiotics and oxybutynin were used to prevent postoperative infection and bladder irritation, respectively.

RESULTS

All patients were repaired in one stage. The mean operative time was 85.9 minutes (range, 77-110 minutes). All patients were discharged after removal of the urethra stent. Mean duration of follow-up was 12.6 months (range, 10-17 months). Of the 50 patients, 48 (96%) voided in a straight stream and had a vertically slit meatus at the tip of a straight circumcised penis (Figure 5). The remaining 2 patients (4%) with midpenile hypospadias developed a small fistula at the site of the native urethral meatus. They underwent multilayer closure after 3 months and the outcome was successful in both cases.

Figure 5. Six Months Following Spongioplasty.

doi: 10.3834/uj.1944-5784.2009.06.13f5



DISCUSSION

The success rate of TIP repair in almost every type of hypospadias defect has approached 90% [1,7]. Urethrocutaneous fistula is the most common complication in up to 16% [1,7]. Interposition of well-vascularized tissue between the penile skin and neourethra is essential to decrease the incidence of fistula [8,9].

Many procedures have been described to achieve vascularized coverage of the suture line [10,11]. In the original article by Snodgrass in 1994 [3], a dorsal-based dartos flap was used for urethral coverage. Although harvesting of dartos tissue from dorsal penile and/or preputial skin has become a standard technique, it has potential complications such as penile torsion, chordee formation, or skin loss when aggressive dissection between the skin and dorsal dartos is conducted. Additionally, it adds some time to reconstruction.

The cosmetic results have become as important as the functional outcomes in hypospadias repair. Belman [10] wrapped the neourethra with a de-epithelialized preputial skin flap, which was rotated to the ventrum from the dorsal aspect. The incidence of fistula was only 3.5%. However,

most of the hypospadias that Belman repaired using the de-epithelialized flap were distal ones in addition to the previously mentioned complications of dartos flap. For this reason, the authors of the present investigation preferred an easy method for urethroplasty using covering from the local surrounding spongiol tissue (spongioplasty). The success rate was 96% with only 4% fistula formation. Mezzine et al [12] reported that the immediate results of spongioplasty are good and long-term follow-up shows maintenance of the cosmetic and functional results. The same results were also reported by Yerkes et al [13].

The authors are aware that a series of 50 patients with a mean follow-up of 12.6 months is not enough to make a comment regarding the results of the technique. A larger series with a longer follow-up period is needed to prove the efficacy of the technique. Because the authors could not achieve a 100% complication-free rate with the surgical technique, they hypothesize that an additional covering by either preputial dartos or de-epithelialized preputial skin can be used to reinforce the repair.

CONCLUSION

Use of the spongiol tissue as an intermediate layer in urethral coverage is a technique that can be easily incorporated into many existing hypospadias repairs. In this small patient series, it contributed to a low rate of urethrocutaneous fistulas. In addition, it alleviates tension on the repair, with low complication rate for penile torsion, chordee formation, and dorsal skin loss. It is also less time consuming than the dartos flap covering.

REFERENCES

- [1] Cheng EY, Vemulapallis N, Kropp BP, et al. Snodgrass hypospadias repair with vascularized flap: the perfect repair for virgin cases of virgin hypospadias. *J Urol*. 2002;168(4, pt 2):1723-1726.
- [2] Peter D. Furness, III: Successful hypospadias repair with a vertical based vascular dartos pedicle for urethral coverage. *AUA*. 2003;169:1825-1827.
- [3] Snodgrass W. Tubularized, incised plate urethroplasty for distal hypospadias. *J Urol*. 1994;151(2):464-465.
- [4] Snodgrass W, Koyle M, Manzoni G, Hurwitz R, Caldamone A, Ehrlich R. Tubularized incised plate hypospadias repair: results of a multicenter experience. *J Urol*. 1996;156(2, pt 2):839-841.
- [5] Retik AB, Borer JG. Primary and reoperative hypospadias repair with the Snodgrass technique. *World J Urol*. 1998;16(3):186-191.
- [6] Firlit CF. The mucosal collar in hypospadias surgery. *J Urol*. 1987;137(1):80-82.
- [7] Guralnick ML, al-Shammari A, Williot PE, Leonard MP. Outcome of hypospadias repair using the tubularized, incised plate urethroplasty. *Can J Urol*. 2000;7(2):986-991.
- [8] Borer JG, Retik AB. Current trends in hypospadias surgery. *Urol Clin North Am*. 1999;26(1):15-37.
- [9] Ulman I, Erikc, IV, Avanoolu A, Gokdemir A. The effect of suturing technique and material on complication rate following hypospadias repair. *Eur J Pediatr Surg*. 1997;7(3):156-157.
- [10] Belman AB. De-epithelialized skin flap coverage in hypospadias repair. *J Urol*. 1988;140(5, pt 2):1273-1276.
- [11] Kirkali Z. Tunica vaginalis: an aid in hypospadias surgery. *Br J Urol*. 1990;65(5):530-532.
- [12] Mezzine S, Beaudoin S, Barga F. Medium and long-term evaluation of spongioplasty in hypospadias repair [in French]. *Prog Urol*. 2005;15(3):519-523.
- [13] Yerkes EB, Adams MC, Miller DA, Pope JC IV, Rink RC, Brock JW III. Y-to-I wrap: use of the distal spongiosum for hypospadias repair. *J Urol* 2000;163(5):1536-1539.

TO CITE THIS ARTICLE: Gamal WM, Zaki M, Rashid A, Mostafa M, Abouzeid AM. Tubularized Incised-Plate (TIP) Repair Augmented by Spongioplasty for Distal and Midpenile Hypospadias. *UIJ* 2009 Jun;2(3). doi:10.3834/uij.1944-5784.2009.06.13.