

Solitary Metastasis of Cervical Carcinoma to the Kidney: A Case Report and Review of the Literature

David C. Hutchings, Emily L. Sammons, Nilay S. Patel, Mark E. Sullivan

Department of Urology, Oxford Radcliffe Hospitals, Oxford, United Kingdom

Submitted August 19, 2009 - Accepted for Publication October 14, 2009

ABSTRACT

A 47-year-old female presented with a history of hematuria and right loin pain 18 months after receiving chemoradiotherapy for advanced cervical carcinoma. A CT scan demonstrated a grossly abnormal right kidney suggestive of either inflammatory or malignant change. A percutaneous biopsy under CT guidance demonstrated squamous cell carcinoma in keeping with metastatic cervical carcinoma. Metastasis of cervical carcinoma to the kidney is extremely rare, with only 8 previous cases reported in the literature.

KEYWORDS: Cervical carcinoma; Renal metastasis; Biopsy; Caval thrombus

CORRESPONDENCE: Dr. David C. Hutchings, Department of Urology, Churchill Hospital, Oxford, OX3 7LJ, UK (dhutchings@doctors.org.uk).

CITATION: *UroToday Int J.* 2009 Dec;2(6). doi:10.3834/uij.1944-5784.2009.12.05

INTRODUCTION

Cervical cancer affects approximately 2,800 women in the United Kingdom (UK) every year. Despite a well-established screening program, over 1,000 women still die annually from the disease. The National Health Services (NHS) cervical cancer screening program is offered to all women in the UK aged 25-64 years. The screening consists of a cervical smear every 3 years for women aged 25-49 years, and every 5 years for those women aged 50-64 years. In 2004, Peto et al [1] estimated that the cervical screening program in the UK saves 5,000 lives annually, even though only 30% of all cancers are screen-detected. The remainder may present in the later stages of the disease with pelvic discomfort, intermenstrual bleeding, postcoital bleeding, postmenopausal bleeding, vaginal discharge, leg pain, lymphoedema, as well as systemic symptoms such as weight loss and anorexia. Recognized risk factors for the development of cervical cancer include low socioeconomic status, smoking, immunosuppression, and exposure to the human papilloma virus (HPV) subtypes 6, 11, 16 and 18. The latter has recently been targeted by the introduction of 2 prophylactic vaccines against HPV, given to girls aged 12-13 years who are not yet sexually active.

Tumor grade, stage of the disease, and individual patient factors such as age and comorbidities influence the outcome of cervical cancer. The staging criteria of the International Federation of Gynecology and Obstetrics (FIGO) are used to guide treatment for cervical cancer [2,3] (Table 1).

Locally advanced cervical carcinoma carries a poor prognosis, with relapse rates of up to 70% in those diagnosed with node-positive disease at the time of their initial diagnosis [4]. The pattern of metastasis in cervical cancer is relatively well established. There may be local invasion into structures such as the uterus, vagina, bladder, and rectum. The most frequent sites for those who develop distant metastases include the lungs (21%), lumbar and thoracic spine (16%), para-aortic lymph nodes (11%), abdominal cavity (8%), and supraclavicular lymph nodes (7%) [5]. The median survival of this population is between 12-24 weeks, with the majority of relapses occurring within 2 years of the initial presentation [4]. Metastasis to the kidney is extremely rare, with only 8 previous cases reported in the literature [6].

Table 1. Summary of FIGO and TNM Staging, Surgical-Pathologic Descriptions, and Prognosis of Cervical Cancer (Modified from References 2 and 3). doi: 10.3834/uij.1944-5784.2009.12.05t1

FIGO ^a Stage	TNM ^b Stage	Description	Treatment	5-Year Survival
–	TX	Primary tumor cannot be assessed		–
–	T0	No evidence of primary tumor		–
0	Tis	Full thickness involvement of the epithelium without invasion into the stroma (carcinoma in situ)	<ul style="list-style-type: none"> • Extradiscal hysterectomy Or • Observation (if patient desires fertility and cone biopsy has negative margins) 	>90%
I	T1	Carcinoma limited to the cervix.	<ul style="list-style-type: none"> • Extradiscal hysterectomy Or • Observation (if patient desires fertility and cone biopsy has negative margins) Stage IA ₂ : <ul style="list-style-type: none"> • Modified radical hysterectomy and pelvic lymph node dissection ± para-aortic lymph node sampling 	90%
	T1a1	No visible lesion:		
	T1a2	<ul style="list-style-type: none"> • IA₁ – stromal invasion < 3 mm in depth and ≤ 7 mm in horizontal spread • IA₂ – stromal invasion 3-5 mm with ≤ 7 mm in horizontal spread 		
	T1b1 T1b2	Visible or microscopic lesion with > 5 mm of depth or > 7 mm horizontal spread: <ul style="list-style-type: none"> • IB₁ – visible lesion ≤ 4 cm in greatest dimension • IB₂ – visible lesion > 4 cm 		
II	T2	Invades beyond the cervix, but not to the pelvic wall or lower third of the vagina		60-80%
	T2a	<ul style="list-style-type: none"> • IIA – with no parametrial invasion, involving upper 2/3rd of the vagina 		
	T2b	<ul style="list-style-type: none"> • IIB – with parametrial invasion 		
III	T3	Tumor extends to pelvic wall and/or lower third of the vagina, and/or causes hydronephrosis or a nonfunctioning kidney		50%
	T3a	<ul style="list-style-type: none"> • IIIA – involves lower third of the vagina 		
	T3b	<ul style="list-style-type: none"> • IIIB – extends to pelvic wall and/or causes hydronephrosis or nonfunctioning kidney 		
IV	T4	<ul style="list-style-type: none"> • IVA – invades mucosa of bladder or rectum and/or extends beyond true pelvis 		<30%
	M1	<ul style="list-style-type: none"> • IVB – distant metastases 		

^aInternational Federation of Gynecology and Obstetrics

^bTumor (T)

Regional lymph nodes (N)

- Nx - regional lymph nodes cannot be assessed
- N0 - no regional lymph node metastasis
- N1 - regional lymph node metastasis

Distant Metastasis (M)

- Mx - distant metastasis cannot be assessed
- M0 - no distant metastasis
- M1 distant metastasis

CASE REPORT

A 47-year-old woman presented with intermenstrual bleeding secondary to stage IV cervical cancer. An MRI scan of the pelvis demonstrated full-thickness uterine invasion, with local extension into the bladder and parametrium causing partial obstruction of the right ureter. She was treated initially with radical external beam radiotherapy to the pelvis followed by adjuvant cisplatin-based chemotherapy with brachytherapy boost. Bilateral JJ ureteric stents were inserted to manage her malignant ureteric obstruction. One month later she was diagnosed with a right renal abscess, necessitating an ultrasound-guided aspiration with nephrostomy placement. Cultures from the aspirate grew *Pseudomonas aeruginosa* and she was treated with a course of intravenous ceftazidime. A post-treatment MRI demonstrated regression of the para-aortic lymphadenopathy with no obvious residual pelvic disease.

The patient's persisting right ureteric obstruction was thought to be related to her radiotherapy treatment and was managed using JJ stents. She had routine cystoscopic stent changes every 6 months. Following her initial treatment, she received regular oncology reviews and MRI scans of the pelvis every 6 months to monitor for disease recurrence.

Eighteen months later, the patient was admitted as an emergency complaining of frank hematuria, difficulty voiding, and right loin pain. There was tenderness over the right renal angle, and pelvic examination demonstrated vaginal blood and a thickened vaginal vault. The patient was stabilized with

analgesia, bladder irrigation, and a blood transfusion prior to further investigations.

Initial investigations included routine blood tests, which demonstrated microcytic anemia and an elevated serum C-reactive protein. The serum electrolytes, urea, and creatinine were within normal limits. Urinalysis was strongly positive for blood and protein but negative for nitrites. A CT urogram demonstrated abnormal enhancement of the right kidney, with no recognizable renal parenchyma or surrounding inflammatory changes. In addition, extensive thrombus was demonstrated within the right renal vein and infrahepatic inferior vena cava, with extension into the contralateral renal vein. These changes were thought to represent either a recurrence of the renal abscess, a renal cell carcinoma, an atypical renal tumor, or a venous infarcted kidney. The extent and nature of the caval thrombus were further evaluated with a CT angiogram (Figure 1; Figure 2).

The patient underwent a flexible cystoscopy examination, which showed extensive blood clots in the bladder. The distal end of the right JJ stent was encased by a solid mass adherent to the posterior bladder wall. The mass was evacuated using cystoscopy under general anesthetic. There was no obvious bladder source of the hematuria. Uncertainty regarding the nature of the renal mass led to a percutaneous biopsy, which was undertaken with CT guidance. Histology demonstrated metastatic squamous cell carcinoma (Figure 3a; Figure 3b). There was no evidence of metastatic disease elsewhere in the body.

Figure 1. Abdominal CT Angiogram, Transverse Section.
doi: 10.3834/uij.1944-5784.2009.12.05f1

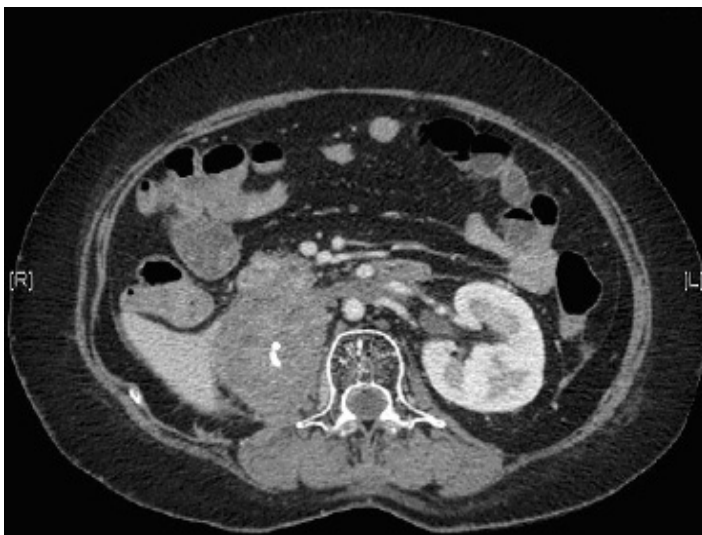

Figure 2. Abdominal CT Angiogram, Coronal Section.
doi: 10.3834/uij.1944-5784.2009.12.05f2

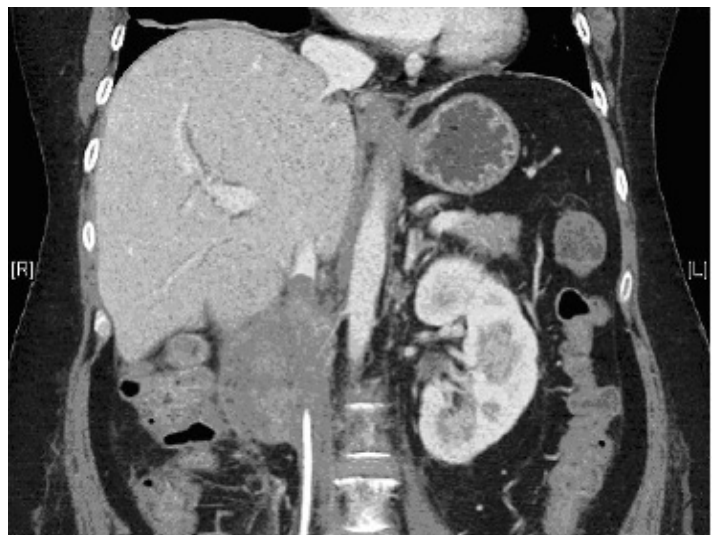

Figure 3a. Renal Biopsy Histology Demonstrating Invasive Squamous Carcinoma (HE Stain, 400x).

doi: 10.3834/uij.1944-5784.2009.12.05f3a

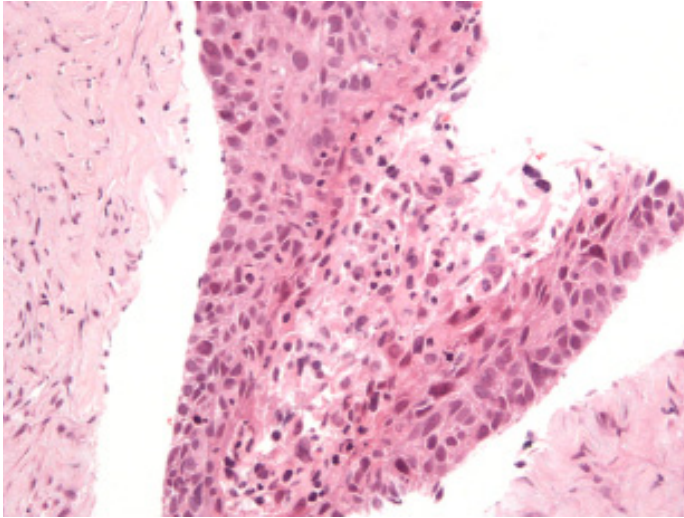
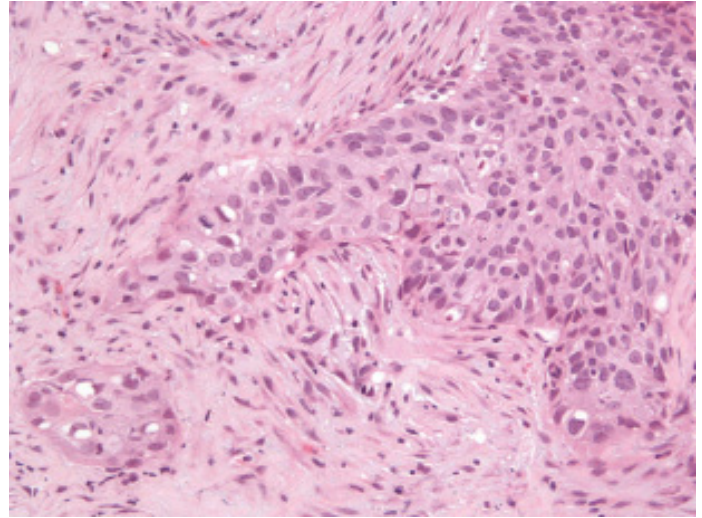


Figure 3b. Renal Biopsy Histology Demonstrating Invasive Squamous Carcinoma (HE Stain, 400x).

doi: 10.3834/uij.1944-5784.2009.12.05f3b



Images provided by Dr. Gareth Turner, John Radcliffe Hospital

A number of factors needed to be considered when making treatment decisions in this case. The presence of a thrombus within the vena cava extending into the contralateral renal vein rendered surgery or embolization dangerous due to the significant risk of losing the contralateral kidney. Although radical nephrectomy with caval thrombectomy is considered a safe and well-established treatment for renal cell carcinoma, this procedure does not apply to metastatic squamous cell carcinoma. In view of the poor prognosis of metastatic cervical cancer, the decision was made not to operate and to manage the case with palliative radiotherapy.

DISCUSSION

Despite the success of screening programs, cervical cancer remains a significant cause of morbidity and mortality of women worldwide. Its epidemiology with regards to subtypes of the human papilloma virus has been extensively researched. This epidemiological research, together with randomized controlled trials, has contributed to a growing evidence base guiding the investigation and management of patients at the time of their initial presentation. However, the present patient highlights the need for more rigorous studies to help substantiate the optimal treatment for individuals affected by more advanced or recurrent disease.

In keeping with most of the previously reported cases, this patient developed metastasis to her right kidney only 18 months after her diagnosis of stage IVa cervical carcinoma.

Earlier case reports on the subject have described patients presenting with loin pain and fevers, in whom it was also difficult to differentiate between renal abscess and malignancy [7,8]. The present patient is unusual in that she had renal metastasis of cervical carcinoma in a kidney previously affected by a confirmed abscess. This case highlights the diagnostic value of a percutaneous renal biopsy in guiding treatment when an indeterminate renal mass cannot be accurately diagnosed using cross sectional imaging.

ACKNOWLEDGEMENT

The authors would like to thank Dr. Gareth Turner, who kindly provided the histology images.

REFERENCES

- [1] Peto J, Gilham C, Fletcher O, Matthews FE. The cervical cancer epidemic that screening has prevented in the UK. *Lancet*. 2004;364(9430):249-256.
- [2] Benedet JL, Bender H, Jones H 3rd, Ngan HY, Pecorelli S. FIGO staging classifications and clinical practice guidelines in the management of gynaecologic cancers. FIGO Committee in Gynaecological Oncology. *Int J Gynaecol Obstet*. 2000;70(2):209-262.
- [3] National Comprehensive Cancer Network. Clinical Practice Guidelines in Oncology: Cervical Cancer. http://www.nccn.org/professionals/physician_gls/f_guidelines.asp. Accessed October 16, 2009.

- [4] Friedlander M, Grogan M, US Preventative Services Task Force. Guidelines for the treatment of recurrent and metastatic cervical cancer. *Oncologist*. 2002;7(4):342-347.
- [5] Fagundes H, Perez CA, Grigsby PW, Lockett MA. Distant metastases after irradiation alone in carcinoma of the uterine cervix. *Int J Radiat Oncol Biol Phys*. 1992;24(2):197-204.
- [6] Lin CM, Sun GH, Lee SS, Yu DS, Chang SY, Wu ST. Remote metastatic cervical carcinoma to kidneys mimicking bilateral renal abscesses. *Eur J Cancer Care (Engl)*. 2007;16(6):526-528.
- [7] de La Taille A, Bertrand P, Lemaitre L, Rigot JM, Mazeman E. Bilateral secondary renal neoplasm mimicking renal abscesses. *Eur Urol*. 1997;31(2):249-250.
- [8] Takahashi A, Adachi H, Iwasawa A, et al. Metastatic cervical carcinoma mimicking kidney abscess. *Int J Urol*. 1998;5(4):377-378.