

## Reoperative Hypospadias Repair Based on Urethral Plate Status

**Mohamed M. Hussein**

Urology Department, Sohag Faculty of Medicine, Sohag University, Sohag, Egypt

Submitted July 7, 2009 - Accepted for Publication August 17, 2009

### ABSTRACT

**INTRODUCTION:** The purpose of the study was to determine the suitable procedure for redo hypospadias repair based on the status of the urethral plate.

**METHODS:** Thirty-five patients with failed hypospadias repair were evaluated regarding the status of the urethral plate, the meatus, residual chordee, and the available surrounding tissues. The mean patient age was 5.8 years (range, 2-12 years). At presentation, 25 patients had the meatus at the distal shaft, 8 at the midshaft, and 2 had complete neourethral stricture. The urethral plate appeared healthy and wide in 30 patients and narrow in 3 patients. All patients had a straight penis with single previous repair. The initial procedure was unknown in 15 patients and was the tubularized incised plate (TIP) procedure in 20 patients. Thirty patients underwent reoperation with TIP procedure, 3 had a Mathieu technique, and 2 had onlay island flap. After repair, cosmetic and functional outcomes were evaluated.

**RESULTS:** Mean follow-up was 23.2 months (range, 12-36 months). Complete wound dehiscence occurred in 3 (8.6%) cases that had the TIP procedure; they are awaiting further repair. No fistulae occurred. Twenty-seven patients had a vertical slit meatus at the tip of the glans and 5 had a rounded meatus. Calibration was satisfactory in all cases using 8-10 Fr plastic catheters. Uroflowmetry was done in 15 (46.9%) patients and found to be within normal limits, with a Q mean of 9.53 mL/s (range, 5-16 mL/s).

**CONCLUSIONS:** Redo TIP urethroplasty is effective and safe when the urethral plate is healthy. When the urethral plate is narrow or the neourethra is stenosed, other alternatives should be considered for repair.

**KEYWORDS:** Hypospadias; Reoperation; Urethral plate

**CORRESPONDENCE:** Mohamed Mostafa Hussein, MD., Urology Department, Sohag Faculty of Medicine, Sohag University, Sohag, Egypt (mmhussein2007@yahoo.com).

**CITATION:** *UroToday Int J.* 2009 Oct;2(5). doi:10.3834/uij.1944-5784.2009.10.08

### INTRODUCTION

Although there have been great advancements in the field of plastic hypospadias surgery, including fine suture materials and magnification, complications are not infrequent [1]. These complications vary widely, from tiny fistulae to complete breakdown of the repair. Treatment of complete repair breakdown can be challenging because of the paucity of tissues available, residual scars, altered urethral plate, and the possibility of decreased tissue vascularity.

There are many encouraging reports on different techniques for salvage hypospadias surgery, but there are few reports on the role of the urethral plate in hypospadias reoperation [2-8]. The purpose of the present prospective investigation was to report the results of redo hypospadias surgery, taking into consideration the condition of the urethral plate as well as other associated factors.

## METHODS

### Participants

Between January 2004 and November 2007, 35 patients with failed hypospadias repair were admitted to the author's department. The mean age of the patients was 5.8 years (range, 2-13 years). Patients were evaluated according to the status of the urethral plate, the location of the meatus, the presence and amount of scar tissue, any residual chordee, the availability of supple tissues surrounding the area, and the type and number(s) of previous repairs.

The condition of the urethral plate was judged by an experienced pediatric urologist in the department who was independent of the investigation. The urethral plate was considered healthy and suitable for tubularization if it was wide (6-8 mm as measured by a caliber), pink in color, and elastic. The urethral plate was considered unhealthy and unsuitable for tubularization if it was narrow (< 6 mm), scarred, and pale. According to this definition, 30 patients had a healthy urethral plate, 3 patients had an unhealthy urethral plate, and 2 patients had neourethral stricture back to the level of the native urethra.

At presentation, 25 patients had the meatus at the distal shaft of the penis, 8 patients had the meatus at the midshaft, and 2 patients had complete neourethral stricture with retention of urine. The 2 patients with stricture had multiple false neourethral passages following trials of catheterization to relieve the retention. These patients were given cystocatheterization. Later retrograde and antegrade urethrograms revealed the stenosed neourethra, which was complete in 1 patient. The level of stenosis was back to the level of the native urethra at the midshaft of the penis.

All patients had a straight penis with no chordee, which was documented intraoperatively with artificial erection. All patients had a single previous attempt to repair the hypospadias. The initial procedure was unknown in 15 patients and was the tubularized incised plate (TIP) procedure in 20 patients. Skin bridges were found in 15 patients.

### Procedures

Parental informed consent was obtained. Patients with a healthy urethral plate (n = 30) were selected to receive TIP urethroplasty; patients with an unsuitable urethral plate (n = 3) were selected to receive the Mathieu procedure; patients with neourethral stricture (n = 2) were selected to receive an onlay island flap (OIF), after cutting the stricture back to the level of the native urethra at the midshaft of the penis.

All procedures were done by a single surgeon (MMH). After repair, cosmetic and functional outcomes were evaluated.

## RESULTS

Patients were admitted the same day of surgery and discharged the next day. The repair was stented for 7-10 days. Cystocatheterization was done only for the 2 cases that had an OIF. It was removed 2 weeks after the repair.

After stent removal, calibration was recommended daily for 2 weeks to avoid obstruction by encrustation or debris and to ensure distal patency. Calibration then was performed weekly for 1 month. Patients were followed for a mean of 23.2 months (range, 12-36 months).

There were no fistulae encountered in any patients. There was complete wound dehiscence in 3 (8.6%) patients that had the TIP procedure. These 3 patients are awaiting further repair.

The 27 patients who had the TIP procedure had a vertical slit-like meatus at the tip of the glans (for examples, see Figure 1 and Figure 2). A rounded meatus was seen in the 3 patients who had the Mathieu procedure and the 2 patients who had the OIF. The final location of the meatus was at the glans in all successful cases.

Calibration was satisfactory in all successful cases (n = 32) using plastic 8-10 Fr catheters. Uroflowmetry was done in 15 (46.9%) patients who were toilet-trained and found to be within normal limits, with a Q mean range of 9.53 mL/s (range, 5-16 mL/s).

## DISCUSSION

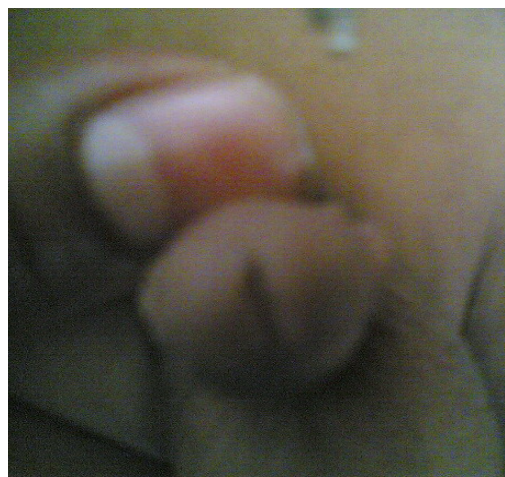
Repair of hypospadias failure can be challenging [2]. Although the preoperative examination may give a preliminary plan for the repair, the actual type of repair is determined only intraoperatively. Many factors are incorporated into the final decision for the procedure. Probably the most important consideration is whether the urethral plate is healthy and wide or scarred and narrow. Other important factors are the residual chordee, the availability of surrounding supple tissue, and the condition of the glans.

Many salvage procedures for reoperative hypospadias have been reported including tubularized incised plate (TIP), the Mathieu procedure, and flap and graft procedures [2-9]. There are some recent reports on the use of TIP urethroplasty in redo hypospadias surgery [3-8]. Snodgrass and Lorenzo [4] reported their initial experience with 15 patients who had failed hypospadias repair. TIP urethroplasty resulted in a functional neourethra and a cosmetically normal meatus in 13 of the 15

Figure 1. Male 8-Year-Old Patient With Vertical Slit-Like Meatus at the Tip of the Glans and 8 Fr Nelaton Catheter Used for Calibration, Following Redo Tubularized Incised Plate Urethroplasty. doi: 10.3834/uj.1944-5784.2009.10.08f1

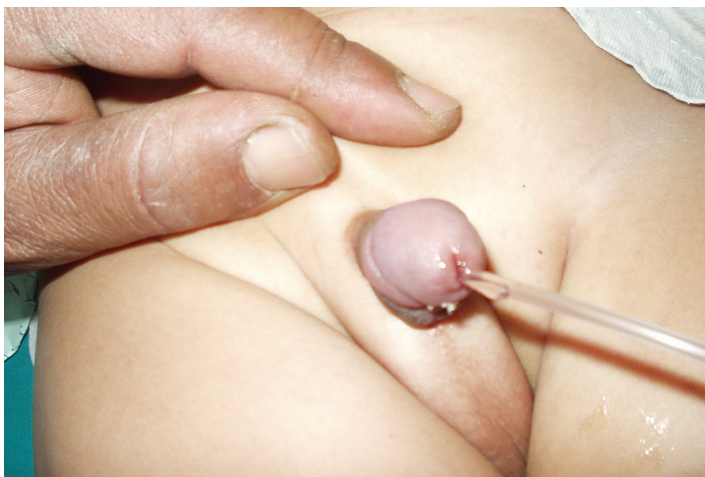

Figure 2. Male 7-Year-Old Patient With Vertical Slit-Like Meatus at the Tip of the Glans, Following Redo Tubularized Incised Plate Urethroplasty. doi: 10.3834/uj.1944-5784.2009.10.08f2



patients. They had 2 cases of fistulae and 1 repair breakdown. Later, Nguyen and Snodgrass [5] updated their experience on an additional 31 patients who had TIP urethroplasty for redo hypospadias. Overall successful outcome was achieved in 28 patients (90%). They had 1 case of a large fistula and 2 cases of wound dehiscence. They concluded that when the urethral plate is intact, TIP urethroplasty achieves a functional neourethra.

Borer et al [7] reported on 25 patients who had hypospadias repair with TIP urethroplasty which included primary and repeat cases. They had satisfactory results, but 1 patient had a meatal stenosis and 5 patients had a fistula.

Shanberg and colleagues [8] reported 13 cases that had TIP procedure for failed hypospadias repair. The cosmetic results were excellent, with 2 complications (1 patient with a glans dehiscence and urethrocutaneous fistula; 1 patient with meatal stenosis) after a follow-up period of 22 months.

More recently, Al-Sayyad et al [2] reported their experience with 28 patients who had 38 redo hypospadias repairs. Their follow-up period was 3.5 years. Twenty-six patients (68.4%) had TIP technique, 3 had Mathieu, 3 had tubularized island flap, 2 had onlay island flap, and 4 had buccal mucosal graft. The complications included 4 cases of fistula, 2 of meatal stenosis, 1 of stricture, and 3 of dehiscence. Elicevik and colleagues [3] reported their study of 100 patients who had TIP urethroplasty for hypospadias reoperation. They had a 26% complication rate, including fistulae (18%), meatal stenosis (5%), dehiscence

(2 %), and stenosis (1%). After treatment of complications, the ultimate success was 97%. The authors concluded that TIP urethroplasty is safe and efficacious for hypospadias reoperations if the urethral plate is favorable.

The present study included 35 redo cases. The TIP technique was done in 30 patients who had a favorable urethral plate. The urethral plate was narrow and unsuitable for tubularization in 3 patients and they had a Mathieu procedure. The 2 patients with a stenosed neourethra had onlay transverse island flaps from the lateral shaft skin. The results of the TIP technique were satisfactory, with a good cosmetic meatus at the tip of the glans.

The present study had 3 cases (8.6%) of complete breakdown, which is comparable to other studies reporting wound breakdown ranging from 2% to 10.7% [2-6]. These cases had inadequate creation of the glanular wings, which were a little tight around the neourethra when they were brought around it. After closure of the neourethra, it was usually covered by the dartous layer from the ventral shaft or in some cases from the lateral sides of the neourethra when the ventral dartous could not be elevated. The importance of the interposed tissue between the neourethra and the skin was previously emphasized [5,7,8]. This may explain the lack of fistulae in the present study.

All patients in the present study had only 1 previous repair. This may have resulted in more healthy, vascular tissues than those available to surgeons in a previous study of patients

Figure 3. Male 6-Year-Old Patient With Previous Complete Neourethral Stricture, Showing Good Stream of Voiding After Onlay Island Flap. doi: 10.3834/uj.1944-5784.2009.10.08f3



with an average of 4 (range, 2-23) prior operations [10]. Other influencing factors may have been lack of chordae in all cases, preserved healthy plate in most cases, and lack of the more severe posterior types of hypospadias. Additionally, the surgeon followed the general principles for plastic surgery including use of loupe magnification. In the few cases that had a narrow urethral plate or stenosed neourethra, satisfactory results were achieved using the Mathieu procedure or OIF (Figure 3).

The meatus was at the glans in all successful cases and was vertical in the TIP group and round in the Mathieu and OIF groups. These results were comparable with those of another study that had 28 of 31 functional neourethrae with a vertical slit meatus after TIP urethroplasty [5].

Calibration was done in all successful cases and no resistance or narrowing was encountered. Uroflowmetry was done in 15 (46.9%) patients who were toilet-trained and found to be within normal limits. This was in agreement with other studies that reported uroflowmetry to be within normal range after hypospadias reoperation [2,11].

Although the present study had a relatively large number of patients when compared with the number in many other investigations, prospective evaluation with a larger sample size is still needed. Another limitation of the present study is the small subset of patients with narrow urethral plate who had

alternative procedures to TIP repair.

## CONCLUSIONS

Although redo hypospadias repair is challenging, it is feasible and safe with good cosmetic and functional outcomes. TIP urethroplasty is safe and effective with low rates of complications when the urethral plate is intact and wide. Coverage of the neourethra with dartous tissue is important to minimize fistula formation. When the urethral plate is narrow or the neourethra is stenosed, other alternatives should be considered for repair.

**Conflict of Interest:** None declared

## REFERENCES

- [1] Snyder CL, Evangelidis A, Hansen G, et al. Management of complications after hypospadias repair *Urology*. 2005;65(4):782-785.
- [2] Al-Sayyad A, Pike J, Leonard MP. Redo hypospadias repair: experience at a tertiary care children's hospital. *Can Urol Assoc J*. 2007;1(1):47-51.
- [3] Elicevik M, Tirli G, Demirali O, Unal M, Sander S. Tubularized incised plate urethroplasty for hypospadias reoperations in 100 patients. *Int Urol Nephrol*. 2007;39(3):823-827.
- [4] Snodgrass WT, Lorenzo A. Tubularized incised-plate urethroplasty for hypospadias reoperation. *BJU Int*. 2002;89(1):98-100.
- [5] Nguyen MT, Snodgrass WT. Tubularized incised plate hypospadias reoperation. *J Urol*. 2004;171(6 Pt 1):2404-2406.
- [6] Simmons GR, Cain MP, Casale AJ, Keating MA, Adams MC, Rink RC. Repair of hypospadias complications using the previously utilized urethral plate. *Urology*. 1999;54(4):724-726.
- [7] Borer JG, Bauer SB, Peters CA, et al. Tubularized incised plate urethroplasty: expanded use in primary and repeat surgery for hypospadias. *J Urol*. 2001;165(2):581-585.
- [8] Shanberg AM, Sanderson K, Duel B. Reoperative hypospadias repair using the Snodgrass incised plate urethroplasty. *BJU Int*. 2001;87(6):544-547.
- [9] Emir L, Erol D. Mathieu urethroplasty as a salvage procedure: 20-year experience. *J Urol*. 2003;169(6):2325-2326.

- [10] Amukele SA, Stock JA, Hanna MK. Management and outcomes of complex hypospadias repairs. *J Urol.* 2005;174(4 Pt 2):1540-1543.
- [11] Hammouda HM, El-Ghonemi A, Bagli DJ, McLorie GA, Khoury AE. Tubularized incised plate repair: functional outcome after intermediate follow up. *J Urol.* 2003;169(1):331-333.