

Perforating Intravesical Intrauterine Devices: Diagnosis and Treatment

Tarek R. Elleithy , Mohamed A. A. Ismail , Samir E. El Ghobashy, Tarek A. Sewalam, Ahmad G. El Baz

Urology Department, Theodore Bilharz Research Institute, Giza, Egypt

Submitted on 12 August 2008 - Accepted for Publication on 15 August 2008

ABSTRACT

BACKGROUND: Intravesical foreign bodies are a reported problem with variable natures. Rarely, it is reported to be an intrauterine device (IUD) that perforates through both the uterine and the vesical walls to lie within the urinary bladder.

OBJECTIVE: We report our experience with 6 cases of IUDs perforating into the urinary bladder.

METHODS: Over 5 years, a total of 6 patients with IUDs perforating to the bladder presented to our facility complaining of LUTS and positive for microscopic hematuria of variable duration. Large, 4- to 5-cm stones were found in 2 patients and were removed via cystolithotomy. IUDs were removed from 3 patients via cystolitholapaxy and endoscopic extraction, and 1 partially perforating IUD with no stone formation was treated via extraction of the device per vagina.

RESULTS: All procedures went well with no complications. Patients received urinary drainage for 1 week postoperatively.

CONCLUSION: IUD perforation to the bladder, with or without stone formation, is a rare event that can be diagnosed and treated easily with minor procedures and minimal complications, provided that the urologist kept the condition in mind.

KEYWORDS: IUD, Bladder stone

CORRESPONDENCE: Mohamed Ali A Ismail, Urology Department, Theodore Bilharz Research Institute, Giza, Egypt, mohadali@hotmail.com

INTRODUCTION

Intrauterine foreign bodies have been historically used as a method of contraception for a long time, but it was not until the early 20th century that intrauterine devices (IUDs) were scientifically introduced and became widely used for this purpose [1]. Though it is a relatively safe method for contraception, it is associated with incidence of perforations (8.7 cases per 1000 introductions) occurring mainly to the intraperitoneal cavity and more rarely to the urinary bladder [2]. There are 70 cases in the literature reporting perforation of the IUDs to the bladder [3]. Intravesical perforation of an IUD can be a simple event that is treated easily by endoscopic

or open retrieval of the IUD. However, complications can arise with the formation of vesicouterine fistula or even vesicoenteric fistula. This causes ureteric obstruction requiring cystectomy with ileal neobladder diversion or resection of the ureter from the inflammatory mass with ureterovesical implantation [4,5].

METHODS

Upon reviewing over 5 years (2000-2005) of data from the registry at the Theodore Bilharz Research Institute, a total of 6 patients with IUDs perforating into the bladder presented to our facility. The patients complained of lower urinary tract symptoms (LUTS) and had microscopic hematuria of variable

duration. Upon presentation, the patients were investigated via clinical examination and urine analysis, culture, and sensitivity. Radiology included abdominopelvic ultrasound and plain urinary tract (UT) and intravenous urography (IVU). Abdominopelvic computed tomography (CT) scans were done for 2 cases.

Out of the 6 patients, 5 were diagnosed with bladder stones of variable sizes partially encasing an IUD perforating to the bladder, and 1 patient was found to have a partially perforating IUD into the bladder. All patients were admitted. The 2 patients who had 3- to 4-cm stones were operated upon via cystolithotomy, and 3 patients were operated upon via cystolitholapaxy and endoscopic extraction of the IUD. One patient with a partially perforating IUD and no stone formation was treated via extraction of the device per vagina, as the strings were still visible. Urethral catheter was fixed and left in for 2 days for patients with endoscopic extraction and for 1 week for patients with open extraction. There were no reported postoperative complications. Below, we present two particularly interesting cases.

CASE ONE PRESENTATION

A 38-year-old female presented to our facility with a history of persistent UTI for the prior 6 months and associated hematuria for the last 2 weeks. She had a long history of lower back pain and was treated for a long-term pelvic inflammatory disease with no improvement. Her history was irrelevant regarding any previous operations or concomitant diseases, but she was admitted 8 years earlier for IUD retrieval and was told it was removed. Plain UT and an IVU showed a bladder stone encasing part of an IUD lying within the urinary bladder, which was confirmed by ultrasonography (fig. 1). Cystoscopy showed a 3-cm stone attached to an intravesical IUD. This was extracted via a small suprapubic incision (fig. 2).

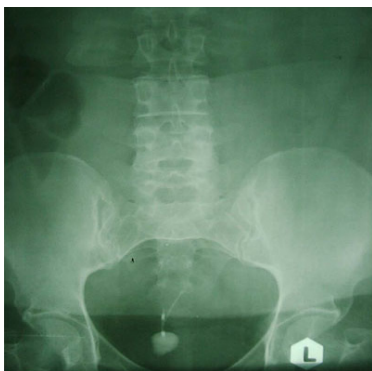

Figure 1. Plain UT Showing the Stone over the IUD
doi: 10.3834/uij.1939.4810.2008.11.06.f1




Figure 2. The IUD with the stone after extraction
doi: 10.3834/uij.1939-4810.2008.11.06.f2

CASE TWO PRESENTATION

A 40-year-old female presented with a long history of LUTS unresponsive to treatment. Abdominal ultrasound showed a large 4-cm bladder stone. The patient gave history that she had not felt the strings of her IUD for some time, but she was reluctant to report this to her gynecologist. CT showed a 4-cm bladder stone overlapping the IUD (fig. 3 and fig. 4). Cystolithotomy was done to remove the stone over the IUD (fig. 5).

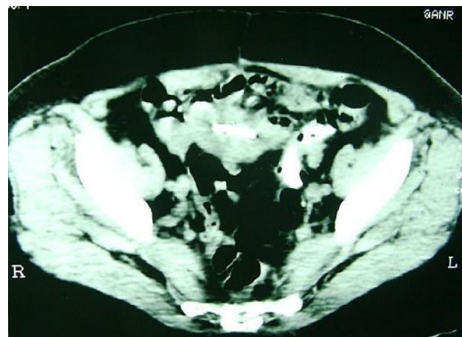


Figure 3. Plain CT showing an IUD within the urinary bladder
doi: 10.3834/uij.1939-4810.2008.11.06.f3

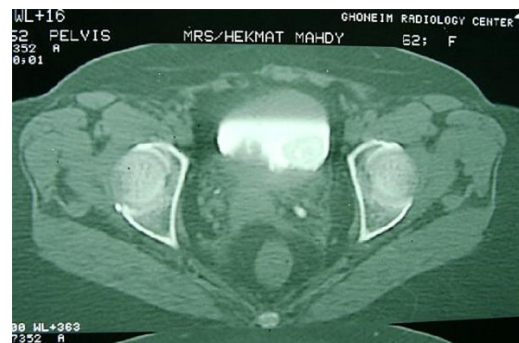

Figure 4. CT with enhancement showing the bladder filled with dye with the IUD inside
doi: 10.3834/uij.1939-4810.2008.11.06.f4

RESULTS

All patients passed the postoperative period and were discharged to their homes with no complications after leaving urinary catheter drainage in for 1 week. On an interesting side note, none of these patients got pregnant despite the fact the contraceptive effect of the IUD was lost and all of them were sexually active.

DISCUSSION

The origin of intravesical foreign bodies is variable. The literature describes foreign bodies ranging from urethral dilators and coffee spoon handles to wires, cables, and surgical instruments. The most frequent access route is transurethral, usually by self-introduction or during a transurethral surgical procedure. Less frequently, these foreign bodies are placed during open or traumatic surgical procedures. Rarely, they can migrate from an adjacent anatomical structure [6]. Urological complications associated with IUDs include perforation to the bladder with or without calculus formation leading to the development of lower urinary symptoms. Also, perforation to the pelvis can cause an inflammatory process that may lead to ureteral obstruction, hydronephrosis or ureterolithiasis with the development of upper urinary symptoms [7]. IUD perforation to the bladder is rarely reported, and to our knowledge there are only 70 cases in the literature. An IUD can find its way to the bladder through perforation from the uterus, which is the most common route, or through faulty transurethral IUD insertion from the start, as reported in 1 case. It can be accidentally discovered during imaging for another reason or due to the development of lower urinary symptoms. Extraction of the perforated IUD can be done via different methods, including open, cystoscopic, and

laparoscopic extraction, or even by just pulling the strings if they were still within the vagina in cases of partial perforation. Upon reviewing the literature, there were no reported cases of pregnancy except 1 report from Turkey with the IUD perforating to the bladder [8], which matches our finding. It is strange, however, that pregnancy with the IUD in place is reported.

CONCLUSION

IUD perforation to the bladder with or without stone formation is a rare event that can be diagnosed and treated easily with minor procedures and minimal complications in most of the cases, provided that the urologist considered this condition.

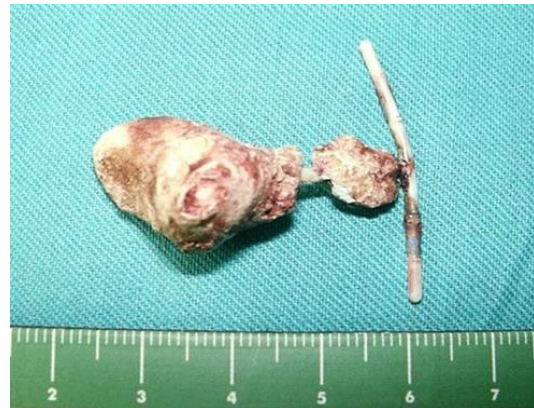

Figure 5. The IUD after extraction partially encased by a stone

doi: 10.3834/uij.1939-4810.2008.11.06.f5

REFERENCES

- [1] Tindall V. Contraception. In: Coate J, ed. Principles of Gynaecology. 5th ed. London: Butterworths; 1987:597.
- [2] Markovitch O, Klein Z, Gidoni Y, Holzinger M, Beyth Y. Extrauterine mislocated IUD: is surgical removal mandatory? Contraception. 2002 Aug;66(2):105-8.
- [3] Istanbuluoglu MO, Ozcimen EE, Ozturk B, Uckuyu A, Cicek T, Gonen M. Bladder perforation related to intrauterine device. J Chin Med Assoc. 2008 Apr;71(4):207-9.
- [4] Fukumoto R, Imanishi O, Tunemori H, Hinata N, Oba T, Yuen K, Yamanaka N. [Subtotal cystectomy and ileal substitution cystoplasty for complicated vesicovaginal fistula: a case report] Nippon Hinyokika Gakkai Zasshi. 2008 May;99(4):601-5.
- [5] El-Hefnawy AS, El-Nahas AR, Osman Y, Bazeed MA. Urinary complications of migrated intrauterine contraceptive device. Int Urogynecol J Pelvic Floor Dysfunct. 2008 Feb;19(2):241-5. Epub 2007 Jul 14.
- [6] Blasco Hernández P, Camacho Martínez E, Quintero Rodríguez R, Campoy Martínez P, Vilches Cocovi E, Salazar Murillo R, García Pérez M. [Migration of an intrauterine device. An unusual cause of bladder foreign body] Actas Urol Esp. 1995 Nov-Dec;19(10):798-801.
- [7] Caspi B, Rabinerson D, Appelman Z, Kaplan B. Penetration of the bladder by a perforating intrauterine contraceptive device: a sonographic diagnosis. Ultrasound Obstet Gynecol. 1996 Jun;7(6):458-60.
- [8] Tunçay YA, Tunçay E, Güzin K, Oztürk D, Omurcan C, Yücel N. Transuterine migration as a complication of intrauterine contraceptive devices: six case reports. Eur J Contracept Reprod Health Care. 2004 Sep;9(3):194-200.

TO CITE THIS ARTICLE: Elleithy TR, Ismail MAA, Ghobashy SEE, Sewalam TA, El Baz AG. Perforating Intravesical Intrauterine Devices: Diagnosis and Treatment. UIJ. 2008 Dec;1(5). doi:10.3834/uij.1939-4810.2008.11.06