



## Giant Leiomyoma of the Ureter Leading to a Loss of Renal Function: A Case Report

Mohamad Sajid Bazaz, Tanveer Iqbal Dar, Nuzhat Tabasum, Mohammad Saleem Wani, Abdul Rouf Khawaja

Submitted March 21, 2013 - Accepted for Publication July 22, 2013

### ABSTRACT

Leiomyoma of the ureter is a very rare benign tumor of mesenchymal origin, which may be very difficult to differentiate from malignant tumors before surgery. With the exception of the numerous fibrous polyps, only the occasional example of leiomyomas, neurofibromas, hemangioma, and fibrolipoma have been reported. To the best of our knowledge only 12 cases have been reported worldwide since 1955, with only 1 case of bilateral ureteric leiomyoma. The aim of this report is to highlight the rarity of this tumor and its impact on renal function.

### INTRODUCTION

Leiomyoma of the urogenital organs is a very rare tumor, and the ureter is an even rarer organ of origin. Total nephroureterectomy is often performed because of the diagnostic dilemma. It usually causes hydronephrosis, making it difficult to diagnose. However, the possibility of malignancy can be ruled out by preoperative ureteroscopic biopsy [1].

We report a case of primary giant leiomyoma of the ureter in which radical nephroureterectomy was performed because of a non-functioning ipsilateral kidney.

### CASE REPORT

A 50-year-old female patient presented with 3 episodes of painless gross hematuria over the last 1 month. There was no other significant history. Baseline investigations included hemoglobin, 11.5 g%; platelet count, 2 lacs/mm<sup>3</sup>; prothrombin time, 13; and INR, 1.10. Her urine examination was normal except for red blood cells full field. Ultrasonography revealed hydronephrotic right kidney with upper hydroureter in the presence of a normal left kidney. Intravenous urography revealed a non-visualized right kidney with a normal, functioning left kidney. Contrast-enhanced computed

tomography revealed a soft tissue mass lesion in the right upper ureter with a hydronephrotic right kidney with thinned out parenchyma. A diuretic renogram revealed a glomerular filtration rate (GFR) of 56 mL and 8 mL on left and right sides, respectively, with an obstructive pattern on the right side. In view of a poorly functioning kidney, the patient was taken up for right radical nephroureterectomy. Operative findings were a grossly hydronephrotic right kidney with thinned out parenchyma, and a ureter dilated up to the ureterovesical junction containing a hard, cord-like mass, extending from L2 up to the ureterovesical junction (UVJ). The mass tapered at both ends with a whitish smooth surface and a firm consistency (Figure 1). The histopathology showed microscopic features consistent with leiomyoma of the ureter with bundles of smooth muscle fibers (Figure 2). The kidney section showed features consistent with hydronephrosis.

### DISCUSSION

The first case of leiomyoma of the ureter was reported by Leighton et al. in 1955 [2]. Since then only 12 cases have been reported [1], making the present case the thirteenth. All cases have been reported in adults (aged 30 to 40 years), apart from 1 case in an infant. The lesions were located in the right ureter in about 60% of cases with a male-to-female ratio of around 1:1. Upper and lower parts were more commonly involved than

**KEYWORDS:** Ureteral tumors, leiomyoma, radical nephroureterectomy

**CORRESPONDENCE:** Dr. Tanveer Iqbal, Clinical Assistant, Department of Urology and Renal Transplant Surgery, Sir Ganga Ram Hospital, New Delhi, India, 110060 (drtanveer@gmail.com)

**CITATION:** *UroToday Int J.* 2013 August;6(4):art 52. <http://dx.doi.org/10.3834/uj.1944-5784.2013.08.11>

the mid-ureter [1].

The mechanism of development remains unclear, although inflammation, chronic stimulation, occlusion, and trauma are suspected. In 2 cases, the patient had a history of ureterolithiasis [1]. Ikota et al. reported a diffused leiomyoma of the ureter as a complication of multiple endocrinoma (MEN) type 1 along with leiomyomas in other organs, including the esophagus, stomach, lungs, uterus, and skin [3]. It has been suggested that the MEN type 1-associated gene may have a causal relationship to multiple leiomyomas [3].

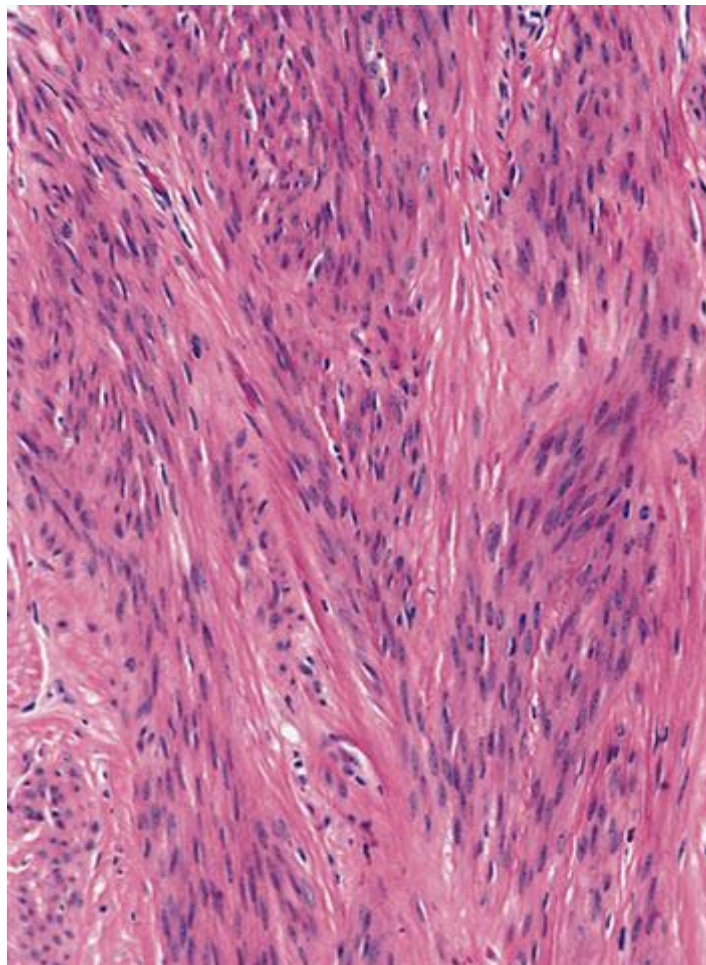
Yashi et al, [4] reviewed the literature and discussed clinical features of 8 cases. The classic triad is uncommon and consists of hematuria (75%), pain (60%), and a hydronephrotic mass (45%). There is an uncommon observation of obstruction to the passage of the ureteric catheter during retrograde pyelography in the area of the filling defect, which may cause bleeding through or around the catheter (Chevassu-Mock sign). If the catheter is successfully manipulated past the obstruction, clear or pink urine is obtained (Marion's sign) [5].

The diagnosis is made by diagnostic imaging such as excretory urography, retrograde urography, or computed tomography

Figure 1. A nephroureterectomy specimen showing the tumor arising from the upper ureter and extending up to the ureterovesical junction. The ipsilateral kidney is hydronephrotic. The bladder cuff is also visible.

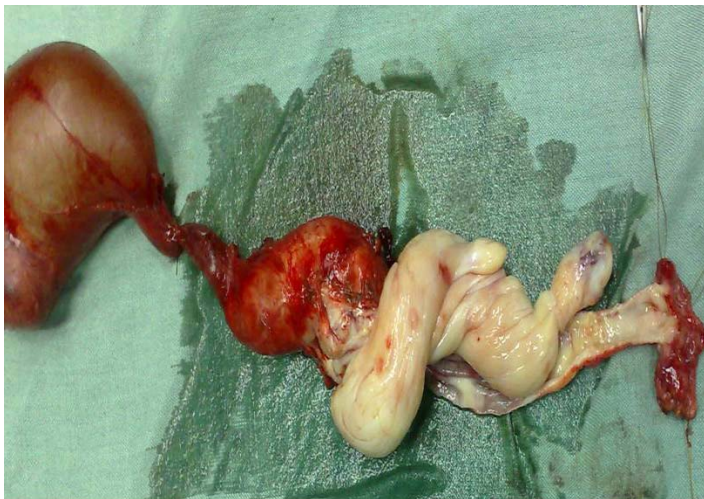

Figure 2. Bundles of elongated smooth muscle cells with an oblong nucleus and eosinophilic cytoplasm.



(CT) and urinary cytology, as for other ureteral tumors, but there are no characteristic findings [1]. Surgical treatment ranges from partial ureterectomy to nephroureterectomy. It has become possible to diagnose benign tumors by preoperative examination as a result of advancements in ureteroscopic technology, and it is important to pay careful consideration to the preservation of renal function [1]. If preoperative studies and intraoperative findings suggest a benign lesion, ureterotomy and biopsy of the lesion for a frozen section may be recommended, with either excision of the tumor or segmental ureteral resection. Such a conservative approach is probably justified in a child if the ipsilateral kidney function is normal. In adults with a poorly functioning kidney, as was the present case, nephroureterectomy is the logical option [5].

Leiomyoma of the ureter should be considered in the differential diagnosis of a ureteric tumour, especially in a young adult

presenting with gross hematuria.

## REFERENCES

1. Katsuya, N., Y. Yoshiaki, et al. (2006). "A case of primary leiomyoma of the ureter." *Int J Urol* 14: 248–250.
2. Leighton, K. M. (1955). "Leiomyoma of the ureter." *Br J Urol* 27(3): 256-257. [PubMed](#)
3. Ikota, H., A. Tanimoto, et al. (2004). "Ureteral leiomyoma causing hydronephrosis in Type 1 multiple endocrine neoplasia." *Pathol Int* 54(6): 457-459. [PubMed](#) | [CrossRef](#)
4. Yashi, M., S. Hashimoto, et al. (2000). "Leiomyoma of the ureter." *Urol Int* 64(1): 40-42. [PubMed](#)
5. Shah, S. A., P. Ranka, et al. (2004). "Leiomyoma of ureter - a rare cause of intractable hematuria and clot retention." *Indian J Urol* 20: 181-182.