



Common Laboratory Values Are Unreliable in Identifying the Presence of Metastatic Renal Cell Carcinoma in the Liver and Bones

Joshua E. Logan, David A. Staneck, Mary H. James, Jack W. Lambert, Robert W. Given, Raymond S. Lance, Michael D. Fabrizio, Stephen B. Riggs

Department of Urology, Eastern Virginia Medical School, Norfolk, Virginia, USA

Submitted April 16, 2013 - Accepted for Publication July 14, 2013

ABSTRACT

Introduction: Evaluation of patients with newly diagnosed renal cell carcinoma (RCC) often includes evaluating serum levels of aspartate aminotransferase (AST), alanine aminotransferase (ALT), and alkaline phosphatase (ALP). Traditional teaching is these laboratory values, if elevated, may indicate the presence of metastatic disease to the liver (AST and ALT) or bones (ALP). We analyzed our institutional RCC database to determine how consistently aberrations in these values were present when metastatic RCC was present.

Materials and Methods: A retrospective chart review was completed, identifying 315 patients diagnosed with RCC who had AST, ALT, and ALP values available for review. Overall rates of aberration, as well as rates of aberration in those patients presenting with metastatic RCC, were calculated.

Results: Of the 315 patients in the study cohort, 61 (19.4%) presented with an elevation in 1 or more of the laboratory values in question. Of these 61 patients, 58 (95%) presented with clinically localized disease. The remaining 3 patients (5%) presented with lung metastasis identified on imaging and had isolated elevations of ALP ranging from 130 IU/L to 278 IU/L; these 3 patients were of the 9 in the cohort who presented with lung metastasis. Five patients presented with metastatic lesions to the bone with no elevation of ALP present. Five patients presented with metastatic lesions to the liver, and none of these patients had any elevation of ALT or AST. However, 1 of these 5 patients did have minimal elevation in ALP, 130 IU/L, but also had a concomitant lung metastasis.

Conclusion: Elevation in ALP, while not seen in patients with bone metastasis in this cohort, was present in 33.3% of patients presenting with lung metastasis. Therefore, an identified aberration in ALP may be considered to direct closer pulmonary evaluation. Regarding AST and ALT, elevations of these laboratory values were not present in any patients with liver metastasis. These observations highlight that AST, ALT, and ALP are unreliable in suggesting the presence of metastatic RCC lesions in liver or bone, and underscore the importance of imaging.

INTRODUCTION

Patients that have been referred for evaluation and management of a renal mass routinely undergo radiographic as well as metabolic evaluation. Metabolic evaluation often includes a comprehensive metabolic panel, which provides information regarding aspartate aminotransferase (AST), alanine aminotransferase (ALT), and alkaline phosphatase

(ALP). AST, ALT, and ALP are all expressed in liver tissue as well as other tissue types, including ALP expression in bone [1]. Elevations in 1 or more of these enzymes may herald any number of entities. Specifically of interest in this population would be the presence of metastatic renal cell carcinoma (RCC). Campbell-Walsh Urology indicates that these changes may indicate advanced disease, which is consistent with traditional teaching: An elevation in any of the 3 enzymes may indicate

KEYWORDS: Renal cell carcinoma, metastases, laboratory values, AST, ALT, alkaline phosphatase

CORRESPONDENCE: Joshua E. Logan, MD, Fellow, Institute of Urologic Oncology, Department of Urology, David Geffen School of Medicine, University of California, Los Angeles, California, United States (jelogan@mednet.ucla.edu)

CITATION: *UroToday Int J.* 2013 August;6(4):art 46. <http://dx.doi.org/10.3834/ujj.1944-5784.2013.08.05>

hepatic metastasis, while elevations in ALP may indicate bone metastasis [2].

With high-quality cross-sectional imaging available for patients diagnosed with a renal mass, some liver and bone lesions can be identified depending on the technique of the study and the regional extent of imaging [3,4]. Given that some liver or bone metastases may be missed radiographically, it would be useful to have an adjunct that reliably identified metastases to 2 of the more common sites of metastasis for RCC. To our knowledge no report has been published indicating how consistently AST, ALT and ALP indicate the presence of liver or bone metastases in patients with RCC.

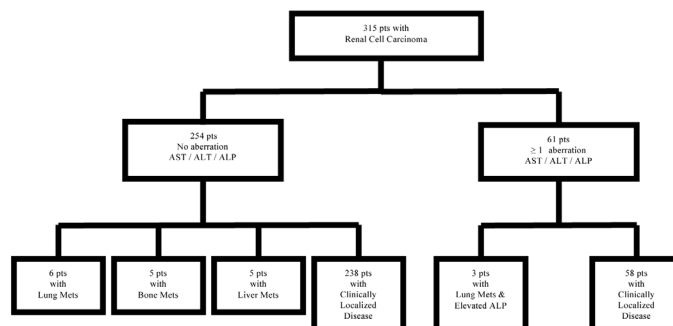
MATERIALS AND METHODS

We reviewed our institutional RCC database and identified 315 patients for whom a complete data set was available, including AST, ALT, and ALP values, as well as radiographic information regarding the presence and location of metastasis. Patients were excluded if this data was unavailable for review. Institutional standards of normal ranges for each laboratory value are as follows: AST 5-37 IU/L; ALT 5-40 IU/L; and ALP 25-115 IU/L. Patient history of bone or hepatic disease, which could have also accounted for elevations of enzymes in the absence of metastatic RCC, was unavailable for review; however, it should be noted that elevated enzymes, regardless of cause, were evaluated appropriately. A history of alcohol consumption was only recorded as yes or no; quantity data was not available for review. Computed tomography (CT) or magnetic resonance imaging (MRI) of the abdomen and pelvis were available for review on all patients in the cohort. A chest X-ray was also available for review in all patients, and a chest CT was available in some patients. The indication for chest CT varied between patients and did not necessarily indicate an abnormal chest X-ray. Bone scans were only obtained if there was reasonable clinical suspicion for the presence of bone metastasis. Overall, aberration rates of AST, ALT, and ALP were calculated, as well as for each enzyme, respectively. We also calculated the rates of aberration specifically in those patients presenting with metastatic RCC.

RESULTS

Of the 315 patients in the study cohort, 61 (19.4%) presented with an elevation in 1 or more of the laboratory values in question. Elevations in AST were identified in 19 (6.03%) of the patients; elevations in ALT were identified in 23 (7.30%) of the patients; and 33 (10.5%) of the patients had elevations in ALP. Of the 33 patients with ALP elevations, 29 (88.7%) had no elevations in the other 2 enzymes. Whereas 8 (42.1%) of the 19 AST elevations were AST only, and 11 (47.8%) of the 23 ALT elevations were ALT only.

Figure 1. Categorization of 315 patients with RCC according to AST, ALT, ALP, and metastatic status.



Of these 61 patients with elevated enzymes, 58 (95%) presented with clinically localized disease. The remaining 3 patients (5%) presented with lung metastasis identified on imaging and had isolated elevations of ALP ranging from 130 IU/L to 278 IU/L; these 3 patients were of the 9 in the total cohort who presented with lung metastasis. Five patients presented with metastatic lesions to the bone with no elevation of ALP present. Five patients presented with metastatic lesions to the liver, and none of these patients had any elevation of ALT or AST. However, 1 of these 5 patients did have minimal elevation in ALP, 130 IU/L, and also had a concomitant lung metastasis.

It should be noted that of the 315 patients, 275 (87.3%) reported on alcohol consumption, and 166 (60.4%) of those patients reported that they did consume alcohol. Of the 61 patients with elevated enzymes, 28 reported no consumption of alcohol, 21 reported that they do consume alcohol, and 12 had an unknown alcohol consumption status.

The overall categorization of patients is demonstrated in Figure 1, and the sensitivity, specificity, positive predicted value, and negative predictive value for each enzyme have been calculated and presented in Table 1.

DISCUSSION

The evaluation of common laboratory values as part of patient work-up for RCC is commonplace. While the practice of obtaining an extended chemistry panel serves more than 1 purpose, it has been used in part to grossly survey for the presence of liver or bone metastasis, as the presence of metastasis would change the clinical picture and potentially change the management plan. Campbell-Walsh Urology does not state that this practice is considered standard to the evaluation, but it does state that it may indicate the presence of advanced disease. The understanding as to why these changes can be detected in

Table 1. Predictive values for AST, ALT, and ALP in identifying the presence of metastatic RCC.

| Sensitivity | Specificity | PPV | NPV | |
|--------------------------|-------------|-----|-----|-----|
| AST for liver metastases | 0% | 94% | 0% | 98% |
| ALP for liver metastases | 20% | 90% | 3% | 99% |
| ALT for liver metastases | 0% | 89% | 0% | 98% |
| ALP for bone metastases | 0% | 89% | 0% | 98% |
| ALP for lung metastases | 33% | 90% | 9% | 98% |

the laboratory values is related to the destructive nature of the metastasis to host tissue; metastatic lesions in the liver or bone can result in elevations in these enzymes secondary to perturbations in the normal cellular physiology of hepatocytes or osteocytes.

It was our purpose to determine how useful this practice is by looking at a cohort of patients with RCC to identify how often the presence of an elevated AST, ALT, or ALP actually identified a patient with a metastatic lesion to the liver or bone. In the cohort of patients that was evaluated, no patients with an elevated AST or ALT were found to have metastasis to the liver; conversely, 5 patients were identified who had metastasis to the liver but had no evidence of AST or ALT elevation. Similarly, none of the 5 patients identified with bone metastases had elevations in ALP. This raises the question, in patients presenting with liver or bone metastases, why were there no aberrations seen in these enzymes? One possible explanation could be the burden of the metastasis was not significant enough to disrupt the host tissue to produce changes in the levels of these enzymes at a clinically detectable level.

An additionally interesting finding was that 3 of the 9 patients with lung metastases had isolated elevations in ALP. This finding of elevated ALP in the presence of lung metastases should not be unexpected given that pulmonary tissue is known to express ALP [5]. Whether these elevations in ALP definitively represented perturbation of the pulmonary tissue by the presence of metastasis or an unrelated coincidental elevation in ALP secondary to some other tissue that expresses this enzyme is unclear and would not be discernable without the use of electrophoresis to determine which tissue-specific isoenzyme is elevated. However, it should be noted that each of these 3 patients with lung metastases were diagnosed with the chest X-ray that is routinely ordered as part of the initial evaluation.

The etiology of the elevated enzymes in the remaining 58 patients is unknown, but it is possible that some were secondary to Stauffer's Syndrome, a paraneoplastic syndrome, which is

non-metastatic, nephrogenic hepatic dysfunction [6]. Others may have been secondary to non-related bone pathology or hepatobiliary dysfunction, such as secondary to alcohol consumption, as discussed above. However, regardless of the cause, it remains that elevations did not routinely identify metastasis to the liver and bone per the traditional teaching. The elevated ALP identified in a third of the patients in this cohort with lung metastasis did raise the question of whether or not an elevated ALP could be useful in identifying lung metastasis. This would require confirmatory studies with electrophoresis to ensure that the elevated ALP is the pulmonary-specific isozyme. This may be a worthwhile pursuit given that an elevated ALP has been reported to have negative predictive value on survival in RCC patients [7,8]. More generally, given that ALP is known to predict adverse outcomes in RCC patients, ALP should be further investigated as to its value in risk stratifying RCC patients; this could potentially be beneficial in making decisions regarding patient management with implications for treatment, as well as for surveillance following therapy.

Overall, these numbers are small and it would be useful to determine if this pattern is consistent in a larger cohort. Nonetheless, these findings raise questions regarding the utility of obtaining the comprehensive metabolic panel in patients with RCC for the purposes of screening for metastatic disease. Our data suggest that the practice is not very useful for identifying metastasis to the liver or bone, but may be useful in identifying lesions in the lungs. If a patient with a renal mass consistent with RCC has a negative chest X-ray and an elevated ALP, in the absence of bone pain to suggest bone metastasis, or evidence to suggest liver metastasis, closer pulmonary evaluation could be considered.

Our study is not without limitations, including its retrospective design, as well as a small sample size (including only 19 patients with metastatic disease), which limits its statistical power. In addition, not all patients received a bone scan, as a result of our general practice to only pursue this in the setting of patient-reported bone pain. Nonetheless, it appears that these traditional markers are unreliable indicators of metastatic RCC.

CONCLUSION

Common laboratory values obtained as part of the evaluation of patients presenting with RCC are not routinely elevated in patients with metastatic disease to the liver and bone. ALP is elevated in patients with lung metastasis in some cases. This will require further investigation to determine if this relationship is causative or correlative.

REFERENCES

1. Millán, JL. (2006). "Mammalian alkaline phosphatases: from biology to applications in medicine." *Wiley-VCH*: 337.

2. Wein, A. J., L. R. Kavoussi, et al. (2011). *Campbell-Walsh Urology, 10th ed.* Elsevier-Saunders; Philadelphia, PA.
3. Catalano, C., F. Fraioli, et al. (2003). "High-resolution multidetector CT in the preoperative evaluation of patients with renal cell carcinoma." *AJR Am J Roentgenol* 180(5): 1271-1277. [PubMed](#) | [CrossRef](#)
4. Griffin, N., M. E. Gore, et al. (2007). "Imaging in metastatic renal cell carcinoma." *AJR Am J Roentgenol* 189(2): 360-370. [PubMed](#) | [CrossRef](#)
5. Capelli, A., C. G. Cerutti, et al. (1997). "Identification of human pulmonary alkaline phosphatase isoenzymes." *Am J Respir Crit Care Med* 155(4): 1448-1452. [PubMed](#) | [CrossRef](#)
6. Stauffer, M. (1961). "Nephrogenic hepatosplenomegaly." *Gastroenterology* 40: 694.
7. Lee, S. E., S. S. Byun, et al. (2006). "Prognostic significance of common preoperative laboratory variables in clear cell renal cell carcinoma." *BJU Int* 98(6): 1228-1232. [PubMed](#) | [CrossRef](#)
8. Chuang, Y. C., A. T. Lin, et al. (1997). "Paraneoplastic elevation of serum alkaline phosphatase in renal cell carcinoma: incidence and implication on prognosis." *J Urol* 158(5): 1684-1687. [PubMed](#)