

## Transrectal Sectional Sonography (TRSS) in the Diagnosis and Treatment of Prostatic Abscesses

Salah Elwagdy, Mohamed A-Khalek, Abdalla El-Kheshen, Abdel Aziz Aun, Ahmed Eldaly, Amr Mostafa, Ehab Adel, Ashraf Enite

Submitted January 4, 2012 - Accepted for Publication February 10, 2012

### ABSTRACT

**Aim:** The aim of this study was to assess the effectiveness of transrectal sectional sonography (TRSS) in the diagnosis and treatment of prostatic abscess.

**Materials and Methods:** Eighteen patients with prostatic abscess were the material of the present study. The criteria of abscess collection within the prostate gland and the periprostatic tissues were confirmed by TRSS, which guided the aspiration in all patients.

**Results:** Diagnosis and transperineal needle aspiration of prostatic abscesses were successful in all cases. After the second puncture procedure, recurrence was noted in 2 (11.1%) out of 18 patients, who were further subjected to transurethral unroofing under TRSS vision. The amount of pus drained ranged between 3.6 to 29.3 mL (mean 15.1 mL), compatible with the estimated volume by virtual organ computer-aided analysis (VOCAL) 3D measurements. The organism most frequently involved is *escherichia coli*. All patients received intravenous antibiotics (third generation cephalosporin) after the midstream urine analysis and further proper antibiotics, according to the aspirated pus culture and sensitivity.

**Conclusions:** Transrectal sectional sonography could be a more reliable method in the diagnosis of prostatic abscesses. It can provide precise needle guides into the best drainage location of the abscess cavity and justify transurethral unroofing if persistent recurrence is there.

### INTRODUCTION

Prostatic abscess is a rare disease representing approximately 0.5% of all prostate diseases [1]. It can affect men at any age, but more often if affects patients in the fifth and sixth decade of life. [2]

The clinical diagnosis of prostatic abscess, in the past, was based on digital rectal examination (DRE), which is mostly unreliable and depends mostly on the sense and experience of urologists [3]. Recently, the diagnosis has been facilitated by the development of ultrasound (US) [4,5], computed tomography (CT) [6,7], magnetic resonance imaging (MRI) [6,7], and,

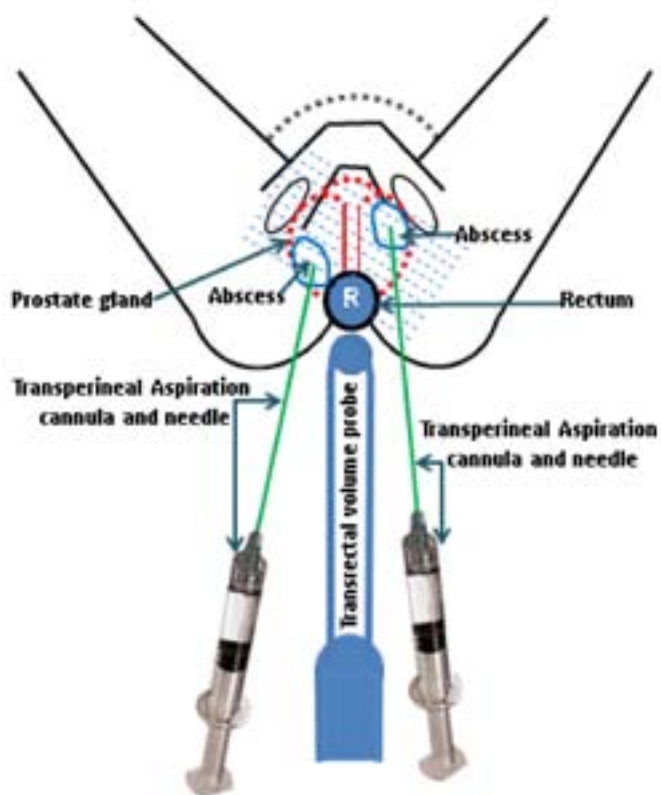
**KEYWORDS:** Transrectal sectional sonography, prostatic abscess, diagnosis and treatment

**CORRESPONDENCE:** Salah Elwagdy, Azhar University, Cairo, Egypt (salah\_elwagdy@yahoo.com).

**CITATION:** *UroToday Int J.* 2012 Apr;5(2):art 01. <http://dx.doi.org/10.3834/uij.1944-5784.2012.04.09>

Figure 1. Diagram demonstrating TRSS of prostatic gland in the diagnosis and transperineal aspiration of abscesses. The dashed lines represent the sectional cuts on which any plane can be selected. The needle tip meets the best cut line at the biopsy guideline summing junction during abscess evacuation.

<http://dx.doi.org/10.3834/uij.1944-5784.2012.04.09f1>



speckles), and the multiple trials in redirecting the tip of needle into the best point for drainage within the cavity of prostatic abscesses [10-12].

Transrectal sectional sonography (TRSS) is an upgrade of 3-dimensional ultrasound (3D US) imaging, based on the production of real-time, multiresolution, very thin (0.5 to 1 mm) contiguous optical slicing of the 3D volume. Each slice has a specific color and represents a specific location on the reference plane. In addition, each slice can be manipulated to the X-Y-Z axes to cope with the needle guideline, which ensures the needle's correct path. This is the essence of the TRSS technique, as it provides real-time enlightenment and mapping for definitive diagnosis and guidance (Figure 1) compared to conventional 2D TRUS.

The purpose of our study was to evaluate the feasibility of TRSS in the diagnosis and mapping for precise puncture drainage of prostatic abscesses, and to discuss our experience of the art of diagnosis and treatment.

To our knowledge, no previous studies addressing transrectal sectional sonography in the diagnosis and treatment of prostatic abscesses have been published before the present investigation.

## MATERIALS AND METHODS

The study protocol was approved by the local ethics committee. We prospectively examined 18 men with prostatic abscesses who presented to our outpatient department at Azhar University Hospital in Cairo, Egypt, between January 2008 and August 2011. This is also the site for the management of urogenital diseases, which covers a large population.

Patients ranged in age from 28 to 78 years old (mean = 42.3 years). Each patient provided written, informed consent and were managed in the outpatient department, except 2 that needed further hospital admissions.

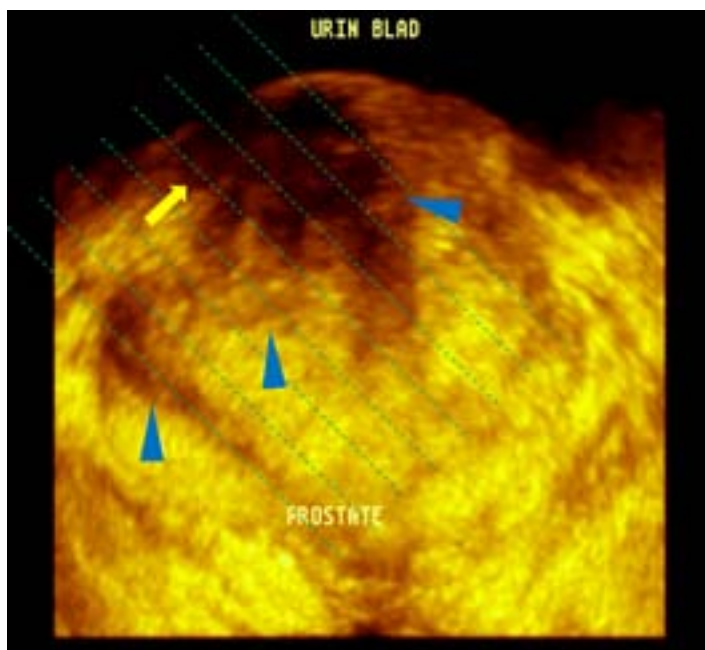
Eight out of the 18 patients with prostatic abscesses were diabetic, 3 patients were on hemodialysis, 2 patients developed prostatic abscesses after catheterization, 3 after US guided prostate biopsy, and 2 patients were on immunosuppressive treatment. Septic fever preceded by chill was present in 7

rarely, scintigraphy [8]. However, conventional 2-dimensional transrectal ultrasound (2D TRUS), introduced by Watanabe and associates in 1971 [9], is the present leading imaging modality for the management of prostatic abscesses.

Nevertheless, the anatomical reference points of 2D TRUS are restricted by the limited viewing planes to guide the needle to the best drainage point of the lesion. Many authors consider the poor-edge definition of 2D TRUS (the main reasons for lesion disorientations are due to the thick plane of viewing and

Figure 2. A 43-year-old man undergoing immunosuppressive therapy presented with fever and urinary frequency. Rectal examination results were unreliable for an abscess. TRSS allows a depiction of a complex echopattern representing fluid collection with debris and septations in the transitional and the central zones of the gland (arrowheads), and in the periprostatic tissue (arrow). Note: Diagrammatic lines are inserted to identify the best course for the needle.

<http://dx.doi.org/10.3834/uij.1944-5784.2012.04.09f2>



patients, and 11 patients reported dysuria, perineal pain, low-back pain, and rectal and bladder tenesmus.

In all patients, digital rectal examination, midstream urine analysis, and blood picture were done. All patients received parenteral antibiotics (third generation cephalosporin) just after obtaining the midstream urine sample, and then were subjected to percutaneous transperineal aspiration guided by TRSS, using an Accuvix V20 ultrasound system (Samsung-Medison America Inc, USA), a 3D volume transrectal probe (5 to 9 MHz) covered with a condom lubricated by gel, and an 18-gauge (20 cm long) Chiba needle. In all patients, abscess

volume was measured using the 3D VOCAL imaging program, where  $\text{volume} = 1/2 [\sum_{i=1}^n (A_{i-1} + A_i) \Delta i - 1]$ .

Patients were placed in the supine position with supported knee-chest semiflexion. After local infiltration anesthesia with Xylocaine 2%, the needle was easily inserted transperineal, using the freehand technique, into the best point of the abscess cavity, guided by the biopsy guideline under live vision. After the aspiration of pus, saline was instilled into the cavity and re-aspirated till the effluent was clear. Patients were given antibiotics for 4 weeks, as per culture results, with a 3-day interval follow-up for 2 weeks. Two patients with large prostatic abscesses, adjacent to the prostatic urethra, underwent unroofing by transurethral resection.

## RESULTS

The most frequent predisposing factor for prostatic abscess in our series was diabetes in 8 of the 18 patients. Fever preceded by chill, dysuria, perineal and low-back pain, and rectal and bladder tenesmus were the most exclusive symptoms reported in our series. In 15 patients, initial DRE suggested abscesses on the basis of painful prostatic enlargement, tenderness, and fluctuation. In the remaining 3 patients, the gland increased in size and was painful but not suggestive of prostatic abscess; the DRE was suggestive of simple acute prostatitis. A midstream urine culture yielded a positive result in 16 patients. *E. coli* was isolated in 14 (77.8%) of the 18 patients. A blood picture revealed elevated leukocytic count in 12 (66.7%) patients (Table 1).

We observed hypoechoic areas that contained inhomogeneous fluid in 15 patients, and homogeneous hypoechoic material in 3 patients using TRSS. In 6 of the 18 patients, the lesion showed internal strands, and there was periprostatic extension in 2 patients (Figure 2). In 4 patients, the fluid collection generally had irregular, ill-defined borders. Nine patients had regular semidefined borders, and 5 patients had irregular semidefined borders (Figure 3). The abscess dimensions ranged between 1.6 and 4.2 cm. The abscesses were located in the paraurethral zone in 3 patients, in the central zone in 4 patients, and in the peripheral zone of the gland in 14 patients; 2 of the latter showed periprostatic extensions. Multiplicity (central and peripheral) of abscesses was noticed in 3 out of the 18 patients (Table 2).

The VOCAL estimated volumes of the abscesses ranged between 3.1 to 27.9 mL (mean: 13.8 mL). The amount of pus drained ranged between 3.6 to 29.3 mL (mean: 15.1 mL).

In all patients, drainage produced rapid clinical improvement and resolved pain and fever. In 16 patients (88.9%), TRSS findings completely normalized after 12 to 14 days, and no residual cavity was visible. In 2 patients (11.1%), persistent recurrence of abscesses adjacent to the prostatic urethra was noticed on follow-up, which needed admission for transurethral unroofing. This procedure was performed under direct TRSS vision and led to a complete recovery in both men.

## DISCUSSION

Considering its rare occurrence, prostatic abscess has remained a serious disease, and a delay in adequate treatment may result in death. The mortality rate of prostatic abscesses has been estimated to range between 3 and 30%. This may be due to the non-specific symptoms of prostatic abscesses [13,14], hence the necessity of early diagnosis and treatment.

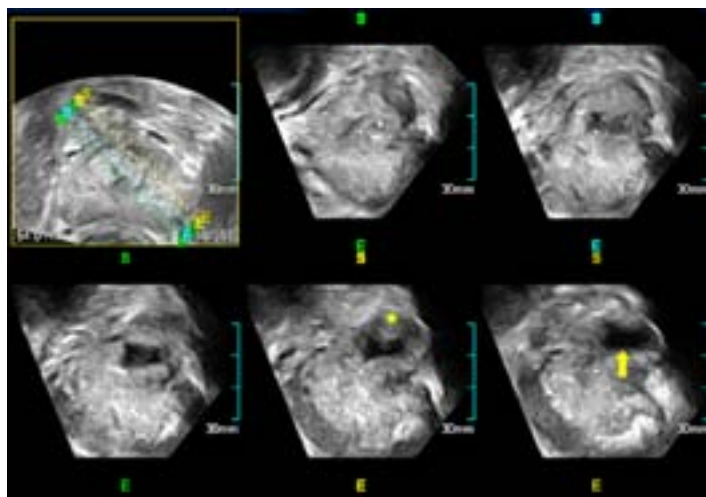
Predisposing factors play an important role in our series, confirmed in 8 patients (44.4%). These predominant factors were diabetes mellitus, and, to a lesser extent, from transrectal biopsy, hemodialysis, immunosuppression, and catheterization, which constituted in 55.6% of our patients. Our data, in accordance with previous series, emphasize the significance of diabetes mellitus, indwelling catheters, instrumentation of the lower urinary tract, bladder outlet obstruction, and acute and chronic bacterial prostatitis [1,3,13].

In our series, fluctuation during DRE was present in 83.3% of patients, which reflects the diagnostic importance of DRE in men with suspected lower urinary tract abnormalities. It also makes clear the necessity for diagnostic imaging to detect the visual data of prostatic abscesses, even those guessed via clinical examination.

The surgical approach, either transurethral or transperineal, are not currently used because perineal incision may result in impotence due to nerve damage, and the transurethral resection would carry the hematogenous spread of germs due to the regional communicating venous drainage. [14-18]

Figure 3. A 71-year-old man with diabetes presented 7 days after prostatic biopsy with severe low back pain and dysuria, and a painful rectal examination. TRSS planes before aspiration show an abscess in his left peripheral zone of the gland, with panoramic display of a hypoechoic fluid collection (arrow) and marginal abscess core (asterisk). The colored guidelines on the reference frame (upper left) were used to identify the best plane (lower right) for correct needle positioning and drainage of collection.

<http://dx.doi.org/10.3834/uij.1944-5784.2012.04.09f3>



Nevertheless, there is still a debate between transrectal and perineal aspiration of prostatic abscesses. The transrectal aspiration procedure, as reported in many references, is easy and fast because it is similar to the well-known technique of transrectal prostate biopsies. Collado et al. [5] reported a success rate of 83.3%, Lim et al. [3] reported a success rate of 85.7%, and Göğüş et al. [19] reported a success rate of (83.3%). Other teams, however, prefer transperineal aspiration as the first-line treatment of any prostatic abscess, which offers the advantages of simplicity and local anesthesia, and it avoids the risk of rectourethral fistula through rectal manipulation or potential pollution recurrence [20-25].

We also think that this debate may arise because of the occasional underestimation of abscess criteria on conventional 2D TRUS due to the lack of definition, dimensions in 3 planes, underestimation of the amount of septa, and sometimes difficulty confirming the real extent within the prostate gland

Table 1. Clinical data and diagnostic approach for 18 patients with prostatic abscesses.

<http://dx.doi.org/10.3834/uij.1944-5784.2012.04.09t1>

Patient	Age (years)	Predisposing factor	Digital rectal examination	Urine analysis infection	TRSS drainage	Culture and sensitivity (abscess)
1	36	hemodialysis	PA	yes	yes	escherichia coli
2	54	diabetes	PA	yes	yes	mixed bacteria
3	63	diabetes	no PA	no	yes	escherichia coli
4	62	diabetes	PA	no	yes	escherichia coli
5	47	immunosuppression	no PA	no	yes	escherichia coli
6	78	diabetes	PA	yes	yes	klebsiella pneumonia
7	72	catheterization	PA	yes	yes	escherichia coli
8	70	prostatic biopsy	PA	yes	yes	candida albicans
9	32	diabetes	PA	yes	yes	escherichia coli
10	43	diabetic	PA	yes	yes	escherichia coli
11	57	prostatic biopsy	PA	no	yes	escherichia coli
12	34	hemodialysis	PA	yes	yes	candida albicans
13	47	diabetic	PA	no	yes	escherichia coli
14	28	catheterization	no PA	no	yes	escherichia coli
15	38	diabetic	PA	no	yes	escherichia coli
16	59	hemodialysis	PA	yes	yes	escherichia coli
17	76	prostatic biopsy	PA	yes	yes	escherichia coli
18	48	immunosuppression	PA	no	yes	escherichia coli

PA: Prostatic abscess

TRSS: Transrectal sectional sonography

and the periprostatic tissues. The value of TRSS can become pronounced due to its very thin, real-time multiresolution display, which can easily eliminate limitations, provide diagnostic confidence, and definite needle positioning. In addition, live TRSS guidance makes the procedure simple and quick, and it does not require any special experience.

We opted for transperineal puncture for several reasons: The entire prostate gland is under transrectal, real-time, high-resolution frame selection, ensures an aseptic pathway for the needle into the prostatic abscess cavity at any location, and provides free-hand control of the needle. Despite this, we had 2 patients with large, persistently recurring paraurethral abscesses that needed surgical transurethral unroofing under

direct TRSS vision so as to ensure complete resection. Depending on our practice in such patients, we do not agree with other reports [21-23] that do not necessitate transrectal ultrasound viewing during prostatic abscess resection.

Current reports indicate that CT and MRI hold no advantage over the more cost-effective 2D TRUS [1,2,6-8,13,14] unless the abscess has penetrated the confines of the prostate gland or there are further abscess foci suspected. In these cases, we found that TRSS may overcome the 2D TRUS limitations. We experienced positive results with our methodology. Thus, we suggest TRSS-guided punctures can become the standard diagnostic and interventional procedure. In any case, optimized



Table 2. TRSS findings in 18 patients with prostatic abscesses.

<http://dx.doi.org/10.3834/uij.1944-5784.2012.04.09t2>

Patient	Hypoechoic area	Echopattern	Size (cm)	Borders	Site	Multiplicity
1	yes	homogenous	2	regular - semidefined	peripheral	no
2	yes	inhomogenous	4	irregular - semidefined	*peripheral	no
3	yes	inhomogenous - septated	1.6	irregular - illdefined	paraurethral	no
4	yes	inhomogenous - septated	3.2	regular - semidefined	peripheral	yes
5	yes	homogenous	2.5	regular - semidefined	*paraurethral	no
6	yes	inhomogenous	3.7	irregular - semidefined	central	no
7	yes	inhomogenous - septated	1.6 - 3.4	irregular - semidefined	+peripheral + central	no
8	yes	inhomogenous	2.5	irregular - illdefined	peripheral	no
9	yes	homogenous	2.1	regular - semidefined	peripheral	no
10	yes	inhomogenous	3	irregular - illdefined	peripheral	no
11	yes	inhomogenous - septated	3.5	regular - semidefined	peripheral	no
12	yes	inhomogenous	1.9	regular - semidefined	peripheral	no
13	yes	inhomogenous	2.1 - 2.7	regular - semidefined	peripheral + central	no
14	yes	inhomogenous - septated	3.3	irregular - semidefined	peripheral	yes
15	yes	inhomogenous	2.9	irregular - semidefined	peripheral	no
16	yes	inhomogenous	2.6	regular - semidefined	*paraurethral	no
17	yes	inhomogenous - septated	2.3 - 4.2	regular - semidefined	peripheral + central	no
18	yes	inhomogenous	3.1	irregular - illdefined	peripheral	yes

†: Two patients with periprostatic extensions

\*: Two patients needed further transurethral unroofing

antimicrobial therapy remains a prerequisite for all therapeutic strategies.

cavity and justify effective transurethral unroofing under direct vision, if persistent recurrence is there.

## CONCLUSION

Our study has proved that transrectal sectional sonography can occupy a prominent place, and it could be a more reliable method in the diagnosis and treatment of prostatic abscesses. It can provide an accurate puncture guide into the abscess

## REFERENCES

1. Granados EA, Riley G, Salvador J, Vincente J. Prostatic abscess: Diagnosis and Treatment. *J Urol.* 1992;148(1):80-82. [PubMed](#)
2. Bhagat SK, Kekre NS, Gopalakrishnan G, Balaji V, Mathews MS. Changing profile of prostatic abscess. *Int Braz J Urol.* 2008;34(2):164-170. [PubMed](#) ; [CrossRef](#)
3. Lim JW, Ko YT, Lee DH, et al. Treatment of prostatic abscess: value of transrectal ultrasonographically guided needle aspiration. *J Ultrasound Med.* 2000;19(9):609-617. [PubMed](#)
4. Weinberger M, Pitlik SD, Rabinovitz M, Morduchowicz G, et al. Per-rectal ultrasonography for diagnosis of and guide to drainage of prostatic abscess. *Lancet.* 1985;2(8458):772. [PubMed](#) ; [CrossRef](#)
5. Collado A, Palou J, García-Penit J, Salvador J, de la Torre P, Vicente J. Ultrasound-guided needle aspiration in prostatic abscess. *Urology.* 1999;53(3):548-552. [PubMed](#) ; [CrossRef](#)
6. Barozzi L, Pavlica P, Menchi I, De Matteis M, Canepari M. Prostatic abscess: Diagnosis and Treatment. *AJR Am J Roentgenol.* 1998;170(3):753-757. [PubMed](#)
7. Oliveira P, Andrade JA, Porto HC, Filho JE, Vinhaes AF. Diagnosis and Treatment of prostatic abscess. *Int Braz J Urol.* 2003;29(1):30-34. [PubMed](#) ; [CrossRef](#)
8. Higashi TS, Hamana T, Takizawa K, Hasebe S, Niio Y, Kuniyasu Y, et al. Using Ga-67 scintigraphy in prostatic abscess. *Ann Nucl Med.* 1995;9(2):89-92. [PubMed](#)
9. Watanabe H, Kaiho H, Tanaka M, Terasawa Y. Diagnostic application of ultrasonography to the prostate. *Invest Urol.* 1971;8(5):548-549. [PubMed](#)
10. Elwagdy S, Razmy S, Ghoneim S, Elhakim S. Diagnostic performance of three-dimensional ultrasound extended imaging at scrotal mass lesions. *Int J Urol.* 2007;14(11):1025-1033. [PubMed](#) ; [CrossRef](#)
11. Elwagdy S, Samy E, Sayed M, Gamal AH. Benign prostatic hyperplasia: clinical benefits on Three-Dimensional Ultrasound eXtended Imaging (3D-XI). *Int J Urol.* 2008;15(4):332-339. [PubMed](#) ; [CrossRef](#)
12. Elwagdy S, Ghoneim S, Moussa S, Ewis I. Three-dimensional ultrasound (3D US) methods in the evaluation of calcular and non-calicular ureteric obstructive uropathy. *World J Urol.* 2008;26(3):263-274. [PubMed](#)
13. Ludwig M, Schroeder-Printzen I, Schiefer HG, Weidner W. Diagnosis and therapeutic management of 18 patients with prostatic abscess. *Urology.* 1999;53(2):340-345. [PubMed](#) ; [CrossRef](#)
14. Hérard A, Brandt B, Colin J, Drancourt E, Youinou Y, Lardenois B. [Prostatic abscesses: what to propose Treatment?]. *Prog Urol.* 1999;9(4):767-771. [PubMed](#)
15. Agarwal A, Praveen CR, Hirachan S, Karmacharya A, Belokar WK. Prostatic abscess a diagnostic dilemma. *J Nepal Health Res Councl.* 2010;8(2):120-123. [PubMed](#)
16. Somuncu I, Sağlam M, Yağci S, L Tahmaz, Taşar M, Ors F. Multiloculated prostate abscess: treatment with transrectal ultrasound guided transrectal needle aspiration and lavage with the saline and antibiotic. *Clin Imaging.* 2003;27(4):251-255. [PubMed](#) ; [CrossRef](#)
17. Weinberger M, Cytron S, Servadio C, Block C, Rosenfeld JB, Pitlik SD. Prostatic abscess in the antibiotic era. *Rev Infect Dis.* 1988;10(2):239-249. [PubMed](#) ; [CrossRef](#)
18. Bachor R, Gottfried HW, Hautmann R. Minimal invasive therapy of prostatic abscess by TRUS-guided perineal drainage. *Eur Urol.* 1995;28(4):320-324. [PubMed](#)
19. Göğüş C, Ozden E, Karaboğa R, Yağci C. The value of transrectal ultrasound guided needle aspiration of prostatic abscess In Treatment. *Eur J Radiol.* 2004;52(1):94-98. [PubMed](#) ; [CrossRef](#)
20. El Harrech Y, Chafiki J, Janane A, Ghadouane M, Ameer A, Abbar M. [US-guided transrectal drainage of prostatic abscesses]. *J Radiol.* 2010;91(2):227-229. [PubMed](#) ; [CrossRef](#)
21. Lim JW, Ko YT, Lee DH, Park SJ, Oh JH, Yoon Y, Chang SG. Treatment of prostatic abscess: value of transrectal ultrasonographically guided needle aspiration. *J Ultrasound Med.* 2000;19(9):609-617. [PubMed](#)
22. Arrabal-Polo MA, Jimenez-Pacheco A, Arrabal-Martin M. Percutaneous Drainage of prostatic Abscess: Case Report and Literature Review. *Urol Int.* 2012;88(1):118-120. [PubMed](#) ; [CrossRef](#)

23. El Harrech Y, Chafiki J, Janane A, Ghadouane M, Ameur A, Abbar M. [US-guided transrectal drainage of prostatic abscesses]. *J Radiol.* 2010;91(2):227-229. [PubMed](#) ; [CrossRef](#)
24. Mason BM, Hakimi AA, Clerkin KJ, Silva JV. Successful percutaneous transperineal drainage of a large prostatic abscess. *Urology.* 2010;76(6):1369-1370. [PubMed](#) ; [CrossRef](#)
25. Basiri A, Javaherforooshzadeh A. Percutaneous drainage for treatment of prostate abscess. *Urol J.* 2010;7(4):278-280. [PubMed](#) ;