

Modified N-Shaped Ileal Neobladder After Radical Cystectomy

Wael Mohamed Gamal,¹ Ahmed Rashid,¹ Mohamed Zaki,¹ Esam Salem,¹ Mohamed Mostafa,¹ Abdelmonem Abuzeid,¹ Mahmoud M. Osman²

¹Sohag University Hospital, Sohag, Egypt; ²Assuit University Hospital, Assuit, Egypt

Submitted May 5, 2009 - Accepted for Publication July 29, 2009

ABSTRACT

INTRODUCTION: The authors report on the feasibility and outcomes of the N-shaped pouch with an afferent tubular isoperistaltic segment as a new technique for creating a capacious, low pressure bladder substitute following radical cystectomy.

METHODS: Between April 2000 and April 2006, 42 patients (36 male, 6 female) with invasive bladder cancer were considered good candidates for orthotopic urinary diversion. All had radical cystectomy with bilateral pelvic lymphadenectomy and orthotopic bladder substitution by an ileal low pressure reservoir (N-shaped) with an afferent isoperistaltic tubular segment. Of the 42 patients, 36 (86%) had squamous cell carcinoma; 6 had transitional cell carcinoma. None of the patients had positive lymph nodes after pathologic examination of the specimen. Thirty-two males and 4 females were available for a median follow-up period of 24.8 months. Follow-up included clinical and radiographic studies to determine functional and oncological outcomes.

RESULTS: Eleven patients (25%) had early complications during the period ≤ 3 months following surgery. Seven of these patients had complications such as wound infection, prolonged ileus, persistent urinary leakage, and deep venous thrombosis that were treated conservatively. One female patient developed a pouch-vaginal fistula that required repair. The remaining 3 patients had oncological failures, 1 of which was isolated urethral recurrence. Late complications occurred in 15 patients (37.5%). These included pouch stones, outflow obstruction, mucus retention, and adhesive bowel obstruction. Daytime and nighttime continence was achieved in 92% and 80% of the patients, respectively, and ureteroileal stricture was observed in 5%. The upper tracts remained unchanged or improved in 95% of the patients.

CONCLUSIONS: Ileal orthotopic bladder substitution (N-shaped) with an afferent ileal tubular segment offers good functional results with good preservation of the renal units. It is considered a safe and technically feasible surgical procedure.

KEYWORDS: N-pouch; Cystectomy; Orthotopic diversion

CORRESPONDENCE: Wael M Gamal, MD, Department of Urology, Sohag University, 31 el nasr Street, Sohag, Egypt (wael_saad_el_dien@hotmail.com).

CITATION: *UroToday Int J.* 2009 Oct;2(5). doi:10.3834/uij.1944-5784.2009.10.02

INTRODUCTION

The standard treatment for urinary diversion has been the ileal conduit. However, in the last 15 years, efforts have been made to preserve patient body image and quality of life by constructing continent bladder substitutes [1]. An orthotopic neobladder shares several normal bladder characteristics which include a continence mechanism and adequate capacity at a low intravesical pressure [1].

In 1979, Camey and Le Duc [2] reported their experience of creating a neobladder from small intestine, with preservation of the urethral sphincter mechanism at cystectomy. By doing so, they showed that this procedure was feasible.

Before 1990, orthotopic neobladder reconstruction was reserved for male patients. The procedure was initially contraindicated in females because the native urethra was routinely removed during a female cystectomy. This was thought to provide adequate resection margins. It was believed that the female patient would be unable to maintain an appropriate continence mechanism after orthotopic neobladder reconstruction. There is now a better understanding of the anatomy of the female continence mechanism, and anatomical dissection supports the idea that the continent outlet is preserved after orthotopic reconstruction [3].

Various methods of continent urinary diversion have recently been developed. The main aim of these procedures was to obtain a high-capacity, low-pressure reservoir that preserved the upper tract and continence [4]. The most popular ileal orthotopic neobladders are the W-shaped pouch described by Hautmann [5,6] and the Studer pouch, which has an afferent tubular isoperistaltic segment [7,8]. Both reconstructions have good functional results and are currently being used by many urologists. Some authors have described minor modifications to these pouches, mainly to improve uretero-ileal anastomosis [9,10].

The present authors describe their experience with the N-shaped pouch using 45 cm of the ileum combined with an isoperistaltic afferent limb of 10 cm, on which both ureters are anastomosed in a simple end-to-side fashion. This type of pouch is very easy to construct and combines features of the Studer and Hautmann neobladder, creating a capacious, low-pressure pouch with an active antireflux mechanism. The purpose of the investigation was to report the feasibility and outcomes of this surgical procedure.

METHODS

Participants

Between April 2000 and April 2006, 42 patients (36 males, 6 females) were considered good candidates for orthotopic urinary diversion. Patients with large tumors, salvage cystectomies, physical impairment, renal impairment, and those with noncompliant mental status were excluded from the present study and treated with simple diversion.

The 42 patients chosen for the study underwent standard pelvic lymphadenectomy with en bloc radical cystectomy and N-pouch ileal neobladder for invasive bladder cancer in the authors' department. The mean patient age was 47 years (SD = 2.5; range, 36-60 years). Of the 42 patients, 36 (86%) had squamous cell carcinoma and 6 patients had transitional cell carcinoma.

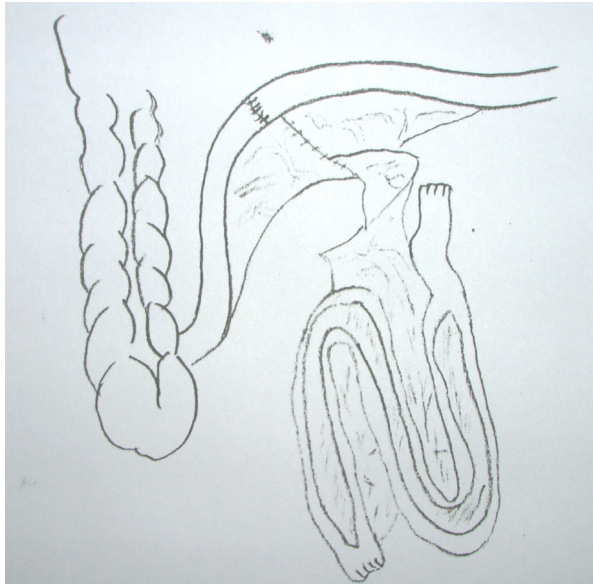
None of the patients had positive lymph nodes after pathologic examination of the specimen. All patients underwent preoperative clinical and laboratory evaluation which showed that they had serum creatinine < 2 mg/dL. Liver functions were adequate with serum albumin > 3 gm/dL and prothrombin concentration > 75%. Only 36 patients (32 male, 4 female) were available for a median follow-up period of 24.8 months.

Surgical Technique

Pelvic lymphadenectomy and cystectomy were performed according to the standard procedure. The specimen was sent for pathologic examination to confirm the staging and assessment of lymphatic invasion. Nerve-sparing surgery was only attempted if it did not compromise radical tumor resection [4].

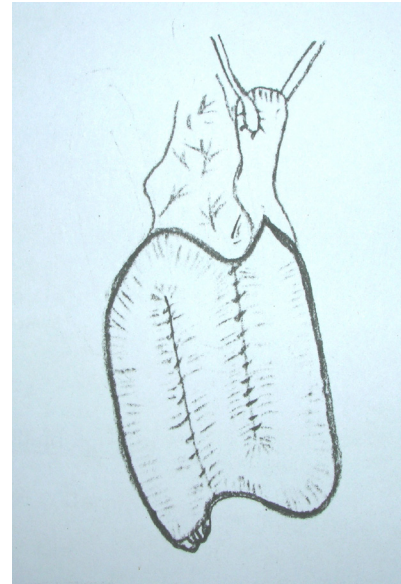In male patients, nerve-sparing radical cystectomy was planned according to the preoperative evaluation of the patient potency. The surgeons attempted to spare the pelvic plexus and nerve fibers lateral to the seminal vesicles by sectioning them anterolateral to the seminal vesicles. After opening the retropubic space, bilateral incision in the endopelvic fascia was done and then carefully extended in an anteromedial direction toward the puboprostatic ligaments. With the puboprostatic ligaments transected, the superficial branch of the dorsal vein is readily apparent in the midline over the bladder neck. The adherent levator ani muscle was gently detached from the prostate, followed by transection of the puboprostatic ligaments (pubovesical ligament). To spare the sphincter, Santorini's plexus was bunched and transected and then the urethra was transected just distal to the apex of the prostate.

Figure 1a. Creation of the Ileal Orthotopic Bladder Substitute, Part A. doi: 10.3834/uij.1944-5784.2009.10.02f1a



An ileal reservoir (together with the afferent tubular segment) was constructed from a 55 cm isolated ileal segment. The distal end of ileal segment measuring 45 cm in length was opened along the antimesenteric border.

Figure 1b. Creation of the Ileal Orthotopic Bladder Substitute, Part B. doi: 10.3834/uij.1944-5784.2009.10.02f1b



The ureters were implanted in end-to-side fashion at the proximal end of the 10 cm afferent tubular segment, according to the Nesbit technique, with 6 fr ureteral stents. The distal segment was then folded transversely into an N-shaped pouch and the neighboring edges were sutured together by seromuscular continuous suture.

In female patients, the urethra was transected distal to the bladder neck, taking the balloon of a previously fixed foley catheter as a landmark of the bladder neck [11]. Proper dorsal support (omental flap, proximal vaginal suspension) and preservation of the autonomous innervation along the lateral vaginal wall are important steps when completing this surgery in female patients.

In all patients, frozen sections of the cut end of the urethra were obtained and examined to ensure a disease-free safety margin.

Ileal Orthotopic Bladder Substitute

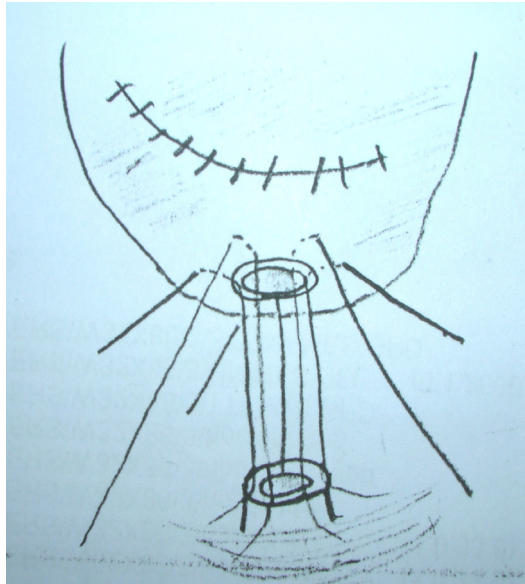
No specific bowel preparation was used other than 2 enemas the evening before surgery. The ileal reservoir, together with the afferent tubular segment, was constructed from a 55 cm ileal segment. The distal mesoileum incision, made approximately 25 cm proximal to the ileocecal valve, was long enough to allow the bladder substitute to reach the urethral stump. Bowel continuity was restored with a single layer, end-to-end seromuscular running suture.

The ileal orthotopic bladder substitute was created using 55 cm of ileum (45 cm for the pouch and 10 cm for the afferent segment) as shown in Figure 1a, Figure 1b, and Figure 1c. After obtaining the ileal segment, both ends of the excluded ileal segment were closed with seromuscular running sutures. Subsequently, the antimesenteric border of the ileal segment was opened, except for the proximal 10 cm which was left unopened to serve as the afferent isoperistaltic limb. The creation of the N-shaped pouch is done in such way that the most caudal end of the plate is used to create a neobladder neck. The proximal limb is used as an isoperistaltic active antireflux segment in which both ureters are reimplanted end-to-side over stents. Finally, a tension free ileal-urethral anastomosis was done over 18 Fr catheter. A suprapubic catheter was then inserted and the pouch was closed.

Postoperative Management

Intravenous alimentation was maintained until normal bowel functions resumed. Third-generation cephalosporines were administered as prophylactic antibiotics. Blood gas was analyzed every other day and sodium bicarbonate was administered as needed.

Figure 1c. Creation of the Ileal Orthotopic Bladder Substitute, Part C. doi: 10.3834/uij.1944-5784.2009.10.02f1c



An 8 mm hole was cut into the lowest part of the pouch. Its mucosa was everted by interrupted suture and anastomosed to the membranous urethra by 6 stitches, with fixation of an 18F silicone foley catheter. Two tube drains were placed in the pelvic cavity and externalized through separate incisions in the abdominal wall.

The reservoir was irrigated with 0.9% NaCl with aspiration of the mucus through the foley catheter every 6 hours. The tubal drains were removed after fluid drainage had ceased. The ureteral stents were removed after 10 days and the patient was discharged.

Four days following discharge, an ascending urethro-pouchogram was performed and the urethral catheter was removed if there was no extravasation. The patients were instructed to void while sitting after removal of the urethral catheter to facilitate good pouch evacuation [12]. The voiding interval was gradually increased from 2 to 4 hours and patients were encouraged not to void early even if minor dribble incontinence ensued. The goal was a final bladder capacity of 400 to 500 mL with urinary continence after 2 to 3 months [12].

Postoperative Follow-Up

After hospital discharge, the patients were scheduled for monthly follow-up visits for the first 6 months and at 3-month intervals thereafter. The median follow-up was 24.8 months. Patient evaluation included symptom analysis for continence

and voiding frequency. The patients were clinically examined for evidence of local recurrence or distant metastasis; CT was done if needed. Ultrasound was done for evaluation of the upper tract at every visit.

The patients were assessed by fluoroscopy and intravenous urogram (IVU) for upper tract dilatation or deterioration, the volume capacity of the pouch, and the amount of postvoid residue (if present). Electrolyte values, blood gases, urine microscopy, and urine culture were also obtained. Videourodynamic testing was done to evaluate the ureteral reflux and pouch capacity.

RESULTS

The mean operative duration for complete en bloc radical cystectomy with bilateral pelvic lymphadenectomy and ileal continent N-shaped pouch with an afferent tubular isoperistaltic segment was 4.3 hours (range, 3-6 hours). Of the 42 patients, 36 were available for mean follow-up of 24.8 months (range 12-30 months).

Early complications (≤ 3 months following surgery). Table 1 contains a list of complications that occurred in the first 3 months for 11 patients (25%). There were no intraoperative deaths, but 1 patient died the day after surgery due to a massive pulmonary embolism. Wound infection was the most common early complication. One patient had a pouch-vaginal fistula that was successfully treated with a transvaginal repair 3 months later. All other early complications were treated conservatively. Diversion-related complications requiring rehospitalization were metabolic acidosis (2 patients) and pyelonephritis and sepsis (1 patient).

Table 1. Early Complications (≤ 3 Months Following Surgery). doi: 10.3834/uij.1944-5784.2009.10.02t1

Complication	Patients		Time of Occurrence Postoperatively (days)
	n	% N	
Postoperative mortality	1	2	1
Prolonged ileus	2	5	6
Acute pyelonephritis	1	2	19
Wound infection	3	7	14
Deep vein thrombosis	1	2	5
Urinary leakage	2	5	
Pouch-vaginal fistula	1	2	45
Total	11	25	

Table 2. Late Complications (> 3 Months Following Surgery).

doi: 10.3834/uij.1944-5784.2009.10.02t2

Complication	Patients		Occurrence Postoperatively (days)	Management
	n	% N		
Pouch stones	2	5	9	Lithotripsy
Urethral stricture	1	2.5	26	Internal urethrotomy
Urethro-ileal stenosis	1	2.5	22	Intermittent dilatation
Mucous retention	1	2.5	7	Irrigation; catheterization
Bowel obstruction	1	2.5	11	Conservative
Metabolic acidosis	2	5	7	Conservative
Oncological failure (recurrence)	3	7.5	14; 36	Urethrectomy; ileal conduit
Uretero-ileal stenosis	2	5	23; 28	Antegrade dilatation; open repair
Incisional hernia	2	5	17	Repair
Total	15	37.5		

Late complications (> 3 months following surgery). Table 2 contains a list of the late complications and their management. Late complications occurred in 15 patients (37.5%). The most common later complication was oncological failure (recurrence) which was seen in 3 patients. One patient had isolated urethral recurrence that developed 23 months after the operation. It was managed by complete urethrectomy and conversion to ileal conduit. The other 2 patients had vulval recurrence 36 months after cystectomy and were managed by pelvic exenteration and ileal conduit. Outflow obstruction in 2 male patients was due to urethral stricture in 1 patient and urethro-ileal stenosis in the other. The former patient was managed by visual urethrotomy and the latter by intermittent dilation. Hypercontinence was not observed in any female patient. Three male patients had outflow obstruction; the remaining patients (92.5%) could void spontaneously without difficulty.

Videourodynamics documented that reflux did not occur during voiding, straining, or coughing. There was a simultaneous increase in intravesical, intraabdominal, and intrarenal pressure during the Valsalva maneuver [13,14]. The functional capacity of the bladder substitute was increased rapidly after surgery by progressive lengthening of the voiding intervals until the desired average pouch capacity of 450 mL was reached.

As seen on IVP, the configuration and function of the upper tract indicated that all except 2 of the 36 patients were stable or had evidence of decompression (Figure 2a; Figure 2b). Deterioration due to ureteroileal anastomotic stricture was noted in 2 patients (Figure 3). Antegrade endoscopic dilation

was successful in 1 patient; open surgical revision was necessary in the other.

Urinary cultures were positive in approximately 10% of patients, usually in association with residual urine. The causes (mostly outlet obstruction or poor voiding habits) were treated. Incisional hernias were reported in 2 patients that were later treated surgically.

Daytime urinary continence improved quickly and reached a plateau 6 months after surgery in 92% of patients. Recurrence of urinary incontinence was pathognomonic for urinary tract infections and decreased with antibiotic treatment. Nighttime continence rates were considerably lower than daytime rates. At 6 months, 80% of the patients were continent at night when using an alarm clock. Only 1 patient with severe incontinence was converted to an ileal conduit.

DISCUSSION

Orthotopic bladder substitution is now considered the method of choice for urinary diversion after cystectomy [15-18]. The procedure is associated with low mortality and acceptable morbidity, despite extended operative time and technical complexity. A postoperative mortality rate of < 2% has been reported in most published data [16,18,19].

Although the authors are at an oncology center and frequently perform radical cystectomy, they carefully selected patients for orthotopic diversion. Their exclusion criteria explain the

Figure 2a. Intravenous Urogram 6 Months After Surgery.

doi: 10.3834/uij.1944-5784.2009.10.02f2a

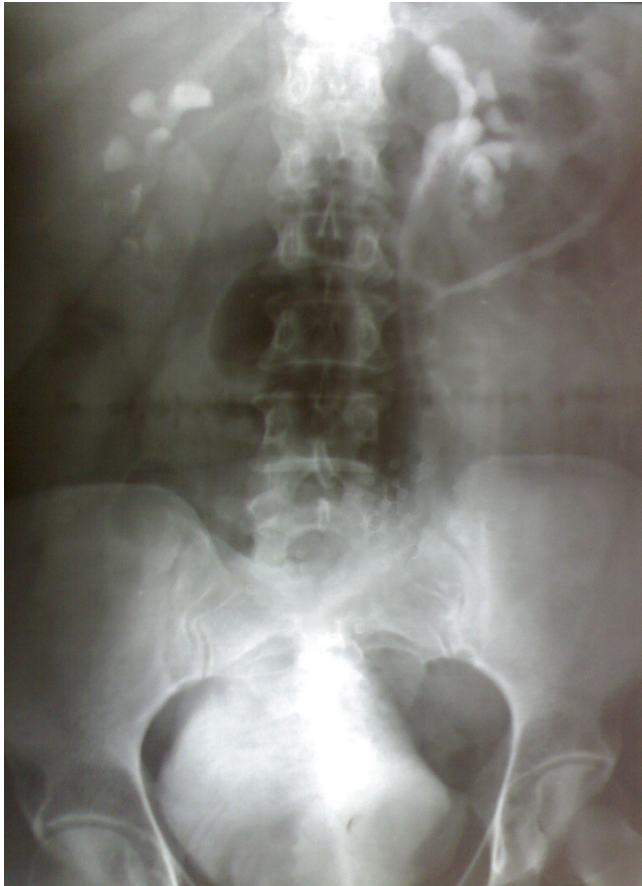
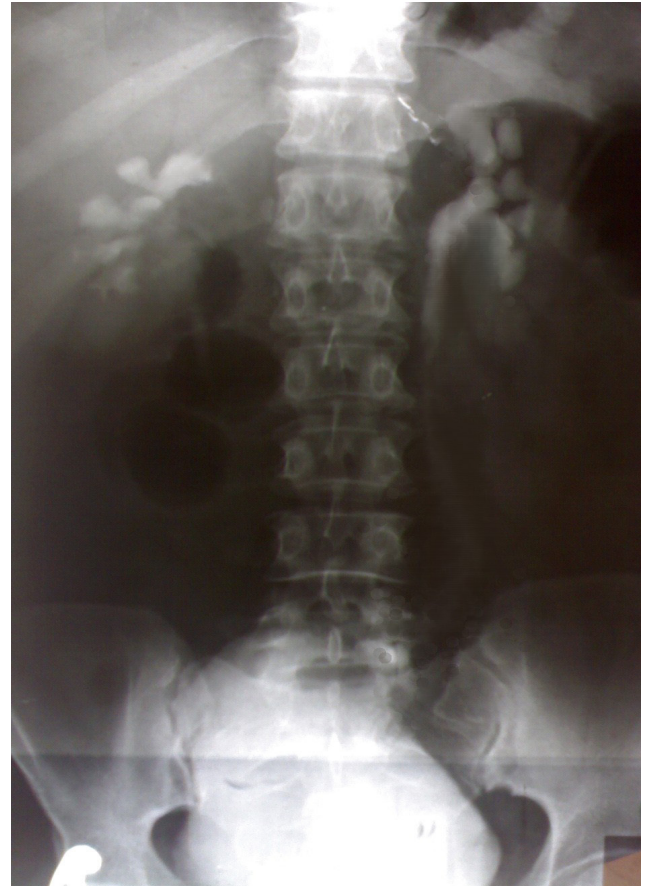
Figure 2b. Intravenous Urogram 12 Months After Surgery.

doi: 10.3834/uij.1944-5784.2009.10.02f2b



relatively small number of patients in the present study.

The incidence of diversion-related complications found in the present investigation is comparable to that of other large series [18,20,21]. Out of the total N of 42 patients, 92.5% could void spontaneously and without difficulty. No cases of hypercontinence were observed in the female patients, although Joniau et al [22] reported hypercontinence in 5 out of 6 women. This phenomenon may eventually be prevented by proper dorsal support (omental flap, proximal vaginal suspension) and preservation of the autonomous innervation along the lateral vaginal wall.

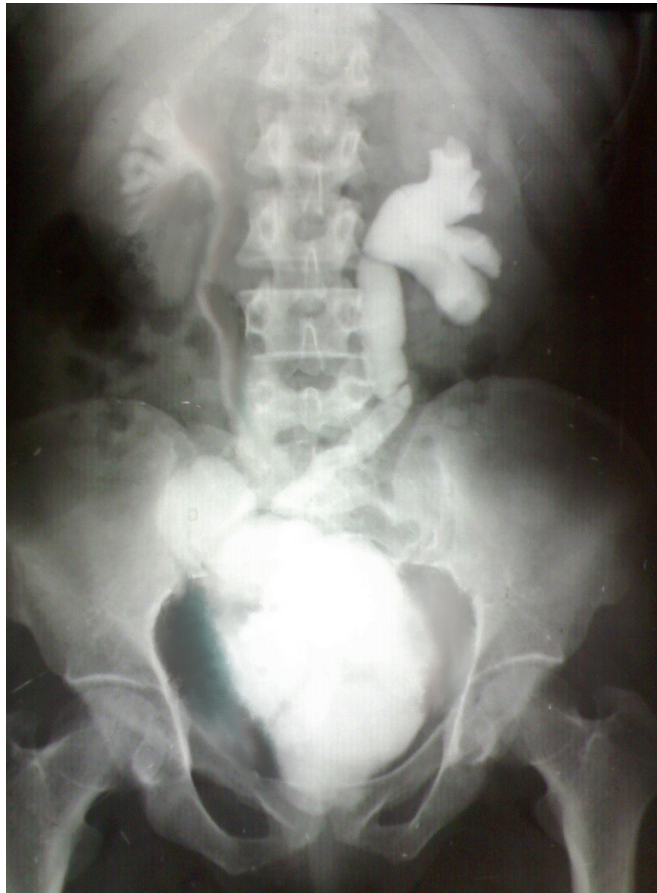Daytime and nighttime continence was reported by 92% and 80% of the patients, respectively, with 3-hour to 4-hour voiding intervals. Similar results have been observed by others [18,19,23-25]. Only 1 patient in the present study required an ileal conduit because of severe incontinence. The need for intermittent self-catheterization was rare; similar low rates

have been noted in other investigations [18,19,24].

Initial concern about tumor recurrences in the urethra became a nonissue. As a result of the proper selection of candidates with negative biopsy from the proximal urethra, only 1 patient had isolated urethral recurrence. Similar data have been reported by others [26-28]. The patient in the current investigation was managed with a complete urethrectomy and conversion to ileal loop conduit.

The surgical procedure described in the present study has several distinct advantages over previously reported techniques. Only 55 cm of distal ileum are required, which is far shorter than the critical length beyond which metabolic complications resulting from reabsorption or malabsorption are anticipated. The most dependent point in the N-shaped pouch can reach the proximal urethral end easily when compared with the Studer pouch. The surgeons infold the U-shaped loop on itself so that the most dependent point in the pouch becomes away from the proximal

Figure 3. Postoperative Intravenous Urogram Showing Left Ureteroileal Stenosis. doi: 10.3834/uij.1944-5784.2009.10.02f3



ureteral end. The N-shaped pouch carries the advantage of an afferent isoperistaltic segment, which acts as an antireflux and allows easy anastomosis with short ureters when compared with the Hautmann pouch. The present technique is simple and less time consuming with short ureters when compared with the T-pouch. The spatulated end of the ureters is anastomosed by a direct mucosa-to-mucosa technique to the intestinal mucosa without passing in a tunnel. Accordingly, the incidence of anastomotic stricture is low (5%) when compared with serous lined extramural ureteral reimplantation [29].

Upper tract preservation was excellent except for those patients with ureteroileal stenosis (5%) because it depends on the capacious, low pressure reservoir containing sterile urine and the unidirectional peristalsis of the ureters and afferent tubular ileal segment. Moreover, unlike the action of a normal bladder, there is no coordinated contraction of the reservoir to cause an isolated intravesical pressure increase and possible reflux during micturition. Voiding is achieved primarily by relaxation

of the urethral sphincter mechanism and then by an increase in abdominal pressure, which act equally on the ureters and the renal pelvis. The lack of any pressure difference makes reflux impossible. Moreover, in the event of a major pressure peak in the bladder substitute for any reason, the membranous urethra would act as a safety valve. For these reasons, the iatrogenic radiographic finding of reflux when overfilling the reservoir should not be over interpreted. It does not have the same urodynamic implications and clinical consequences as in normal or even neuropathic bladders with elevated intravesical voiding pressures. Therefore, if an antireflux procedure other than the dynamic afferent ileal segment (eg, nipples, tunnelled ureters) is used, its possible morbidity must be carefully weighed against any potential benefit [25,30].

Finally, the incidence of stone formation in the present study (5%) is markedly decreased when compared with the stone formation after Kock neobladder construction (13-24%), in which staples are used [18,23].

CONCLUSIONS

Significant progress and evolution in urinary diversion have occurred in the last decade, but there is still no perfect bladder substitute. However, the N-shaped pouch orthotopic neobladder diversion can be performed in men and women in a safe and timely fashion with limited morbidity and good functional outcome. Daytime and nighttime continence are quite acceptable but not absolute.

Conflict of Interest: None declared

REFERENCES

- [1] Benson MC, Seaman EK, Olsson CA. The ileal neobladder is associated with a high success and low complication rate. *J Urol.* 1996;155(5):1585-1588.
- [2] Camey M, Le Duc A. L'entérocystoplastie avec cystoprostatectomie totale pour cancer de la vessie. Indications, technique opératoire, surveillance et résultats sur quatrevingtsept cas. *Ann Urol.* 1979;13:114-117.
- [3] Colleselli K, Stenzl A, Eder R, Strasser H, Poisel S, Bartsch G. The female urethral sphincter. A morphological and topographical study. *J Urol.* 1998;160(1):49-54.
- [4] Kessler TM, Burkhard FC, Perimenis P, et al. Attempted nerve sparing surgery and age have a significant effect on urinary continence and erectile function after radical cystoprostatectomy and ileal orthotopic bladder substitution. *J Urol.* 2004;172(4 Pt 1):1323-1327.

- [5] Hautmann RE. Complications and results after cystectomy in male and female patients with locally invasive bladder cancer. *Eur Urol.* 1998;33(Suppl 4):23-24.
- [6] Hautmann RE. Orthotopic bladder reconstruction: Technique, hazards and outcome. *Curr Opin Urol.* 1997;7(5):299-303.
- [7] Studer UE, Stenzl A, Mansson W, Mills R. Bladder replacement and urinary diversion. *Eur Urol.* 2000;38(6):790-800.
- [8] Studer UE, Zingg EJ. Ileal orthotopic bladder substitutes. What have we learned from 12 years' experience with 200 patients? *Urol Clin North Am.* 1997;24(4):781-793.
- [9] Lippert MC, Theodorescu D. The Hautmann neobladder with a chimney: a versatile modification. *J Urol.* 1997;158(4):1510-1512.
- [10] Schwaibold H, Friedrich M, Fernandez S, Conrad S, Huland H. Improvement of ureteroileal anastomosis in continent urinary diversion with modified Le Duc procedure. *J Urol.* 1998;160(3 pt 1):718-720.
- [11] Ali-el-Dein B, el-Sobky E, Hohenfellner M, Ghoneim MA. Orthotopic bladder substitution in women: functional evaluation. *J Urol.* 1999;161(6):1875-1880.
- [12] Varol C, Studer UE. Managing patients after an ileal orthotopic bladder substitution. *BJU Int.* 2004;93(3):266-270.
- [13] Studer U E, Casanova GA, Zingg EJ. Bladder substitution with an ileal low-pressure reservoir. *Eur Urol.* 1988;14(Suppl 1):36-40.
- [14] Studer UE, Danuser H, Thalmann GN, Springer JP, Turner WH. Antireflux nipples or afferent tubular segments in 70 patients with ileal low pressure bladder substitutes: long-term results of a prospective randomized trial. *J Urol.* 1996;156(6):1913-1917.
- [15] Studer UE, Ackermann D, Casanova GA, Zingg EJ. Three years' experience with an ileal low pressure bladder substitute. *Br J Urol.* 1989;63(1):43-52.
- [16] Skinner DG, Boyd SD, Leiskovsky G, Bennett C, Hopwood B. Lower urinary tract reconstruction following cystectomy: experience and results in 126 patients using the Kock ileal reservoir with bilateral ureteroileal urethrostomy. *J Urol.* 1991;146(3):756-760.
- [17] Hautmann RE, Volkmer BG, Schumacher MC, Gschwend LE, Studer UE. Long-term results of standard procedures in urology: the ileal neobladder. *World J Urol.* 2006;24(3):305-314.
- [18] Meyer JP, Blick C, Arumainayagam N, et al. A three-center experience of orthotopic neobladder reconstruction after radical cystectomy: revising the initial experience, and results in 104 patients. *BJU Int.* 2009;103(5):680-683.
- [19] Hautmann RE, De Petriconi R, Gottfried HW, Kleinschmidt K, Mattes R, Paiss T. The ileal neobladder: complications and functional results in 363 patients after 11 years of follow up. *J Urol.* 1999;161(2):422-428.
- [20] Hautmann RE. Urinary diversion: ileal conduit to neobladder. *J Urol.* 2003;169(3):834-842.
- [21] Shaaban AA, Mosbah A, El-Bahnasawy MS, Madbouly K, Ghoneim MA. The urethral Kock pouch: long-term functional and oncological results in men. *BJU Int.* 2003;92(4):429-435.
- [22] Joniau S, Benijts J, Van Kampen M, et al. Clinical experience with the N-shaped ileal neobladder: assessment of complications, voiding patterns, and quality of life in our series of 58 patients. *Eur Urol.* 2005;47(5):666-672.
- [23] Steven K, Poulson AL. The orthotopic Kock ileal neobladder: functional results urodynamic features, complications and survival in 166 men. *J Urol.* 2000;164(2):288-295.
- [24] Elmajian DA, Stein JP, Esrig D, et al. The Kock ileal neobladder: updated experience in 295 male patients. *J Urol.* 1996;156(3):920-925.
- [25] Studer UE, Danuser H, Merz VW, Springer JP, Zingg EJ. Experience in 100 patients with an ileal low pressure bladder substitute combined with an afferent tubular isoperistaltic segment. *J Urol.* 1995;154(1):49-56.
- [26] Lebreton T, Herve JM, Barre P, et al. Urethral recurrence of transitional cell carcinoma of the bladder. Predictive value of preoperative latero-montanal biopsies and urethral frozen sections during prostatocystectomy. *Eur Urol.* 1998;33(2):170-174.
- [27] Maier SH, Gschwend JE, de Petriconi R, et al. Urethral and upper urinary tract recurrences following orthotopic urinary reconstruction. *J Urol.* 1999;161(suppl.264):abstract 1019.

- [28] Ali-El-Dein B. Oncological outcome after radical cystectomy and orthotopic bladder substitution in women. *Eur J Surg Oncol.* 2009;35(3):320-325.
- [29] Abol-Enein H, Ghoneim MA. Functional results of orthotopic ileal neobladder with serous-lined extramural ureteral reimplantaion: experience with 450 patients. *J Urol.* 2001;165(5):1427-1432.
- [30] Hautmann S, Chun KHF, Currlin E, Braun P, Huland H, Juenemann KP . Refluxing chimney versus nonrefluxing LeDuc ureteroileal anastomosis for orthotopic ileal neobladder: a comparative analysis for patients with bladder cancer. *J Urol.* 2006;175(4):1389-1394.