

## Labial Nodular Fasciitis: A Rarity with Benignity

*Vishwajeet Singh, Dheeraj Kumar Gupta, Rahul Janak Sinha*

*Submitted June 11, 2012 - Accepted for Publication July 23, 2012*

### ABSTRACT

A middle-aged woman presented with a right labial mass that had been gradually increasing for 2 years. There were no other associated symptoms. The local examination of swelling showed a right labial mass of approximately 10 cm x 10 cm, which was non-tender, firm, and had side-to-side mobility. Fine-needle aspiration cytology was negative for malignant cells. The contrast computed tomography (CT) scan of the pelvis showed a large, well-encapsulated homogeneously enhancing mass. The patient was planned for excision of the mass through the transvaginal route. The histopathological examination was consistent with nodular fasciitis.

Nodular fasciitis is a common reactive mesenchymal proliferation that mimics some of the benign and malignant soft-tissue masses. The labium is the preferred location for a number of mesenchymal tumors and tumor-like lesions, including the postoperative spindle cell nodule, aggressive angiofibroma, angiofibrosarcoma, and nodular fasciitis. The urologist/gynecologist must have awareness about this rare lesion, and it must be differentiated from other mesenchymal lesions because of its benign nature.

Herein, we present a case of labial nodular fasciitis that was large, in comparison to those reported in English literature. The patient is asymptomatic and doing well in 1 year of follow-up care.

### CASE REPORT

A 44-year-old woman presented with a right labial mass that had been gradually increasing for 2 years. There were no other associated symptoms. The local examination of the swelling showed a right labial mass of approximately 10 cm x 10 cm, non-tender, firm, and with side-to-side mobility (Figure 1). Her hemogram, renal function test, liver function test, and urinalysis were normal. Fine-needle aspiration cytology was negative for malignant cells. The contrast computed tomography (CT) scan of the pelvis, including the labial cuts, showed a 9 cm x 8 cm, well-encapsulated, homogeneously enhancing oval mass (Figure 2). The patient was planned for excision of the mass through the transvaginal route. An incision over the mass was given over the lateral vaginal wall, and a plane between the vaginal wall and the mass was developed. The mass was excised completely; measuring 9 cm x 7 cm x 6 cm, the cut section was homogeneously

white (Figure 3). Packing the vagina with Vaseline cotton gauze soaked in diluted povidone iodine created gentle pressure over the operated side. The histopathological examination of the specimen revealed proliferated, thin, and elongated or spindle-shaped cells interspersed in abundant fibrocollagenous stroma (Figure 4). The cells had ovoid or elongated nuclei and scanty cytoplasm. Several thin-walled blood vessels were seen. The Van Gieson stain showed abundant collagenous tissue. The histology was consistent with nodular fasciitis. The patient is asymptomatic and doing well in 1 year of follow-up care.

### DISCUSSION

Nodular fasciitis or pseudosarcomatous fasciitis is a group of reactive lesions in the superficial or deep fascia resembling a variety of benign and malignant soft tissue tumors of the vulva [1,2]. Though its most common occurrence is in the

**KEYWORDS:** Nodular fasciitis, benign vulvar lesion, labial mass

**CORRESPONDENCE:** Vishwajeet Singh, MS, MCh (Urology), Chhatrapati Shahuji Maharaj Medical University (Formerly KGMU), Lucknow, Uttar Pradesh, India (vishwajeeturo@sify.com)

**CITATION:** *UroToday Int J.* 2012 October;5(5):art 56. <http://dx.doi.org/10.3834/uij.1944-5784.2012.10.15>

## CASE REPORT

Figure 1. A large, right-sided labial mass showing side-to-side mobility.

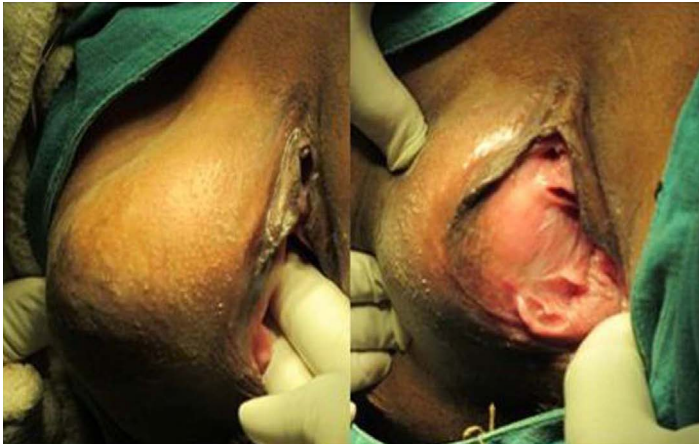


Figure 2. The contrast CT scan of the pelvis showing a well encapsulated, homogenously enhancing oval mass.

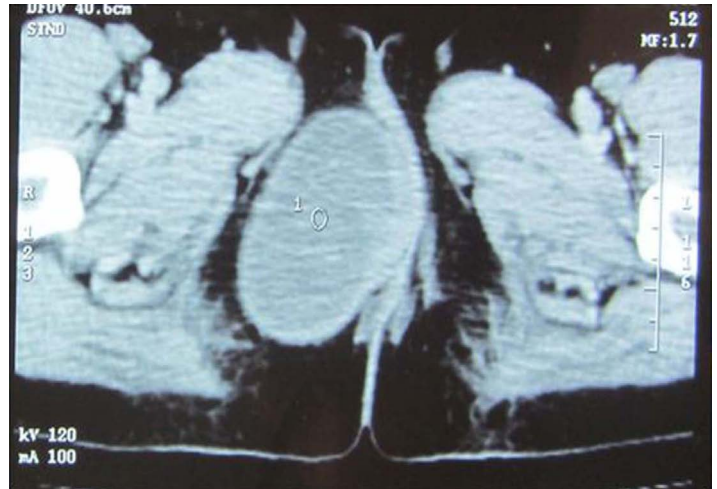
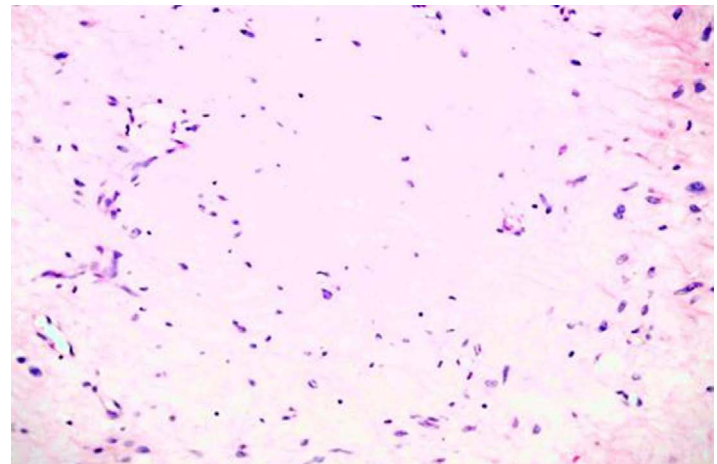


Figure 3. After incision over the lateral vaginal wall; a plane is being developed, the mass was completely excised (9 cm x 7 cm x 6 cm), and was homogenously white on the cut section.

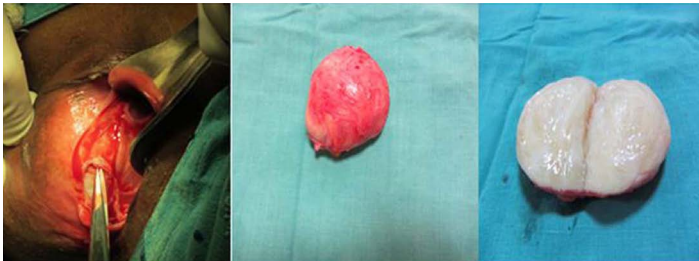

Figure 4. The histopathological examination of the specimen showing proliferated, thin, and elongated or spindle-shaped cells interspersed in abundant fibrocollagenous stroma (H&E stain, 40 x magnification).



subcutaneous tissue of the extremities and trunk, vulvar nodular fasciitis is rare and only 14 cases to date have been reported in literature [1-5]. The perineal soft tissues, including the labia, are the preferred location for a number of other soft tissue lesions such as postoperative spindle-cell nodules, aggressive angiomyxoma, angiomyofibroblastoma, and benign and smooth muscle neoplasms [2-4]. The importance of this lesion lies in its recognition because of histopathological similarity to sarcomas. The immunohistochemistry was done in some of the reported cases; the reason could be the initial difference in opinion regarding histopathology [1,3,4]. The clinical behavior is that it does not metastasize, and a cure is usually obtained with simple excision. No radical surgery is indicated [1-5].

The present case has some unique features. The size of the mass was 9 cm, which was larger in comparison to other cases

reported in English literature (less than 5 cm). The contrast CT scan finding of nodular fasciitis has not been described before. It was a well circumscribed, round-to-oval, homogeneously enhancing mass. The staining was done with a Van Gieson stain, which revealed abundant collagenous tissue with spindle cells, confirming the histopathological diagnosis.

## CONCLUSION

Vulvar nodular fasciitis is a rare benign lesion, and urologists should be aware of its existence. Complete excision is the treatment of choice.

## REFERENCES

1. Aranda, F. I. and J. B. Laforga (1998). "Nodular fasciitis of the vulva. Report of a case with immunohistochemical study." *Pathol Res Pract* 194(11): 805-807. [PubMed](#) ; [CrossRef](#)
2. Gaffney, E. F., B. Majmudar, et al. (1982). "Nodular fasciitis (pseudosarcomatous fasciitis) of the vulva." *Int J Gynecol Pathol* 1(3): 307-312. [PubMed](#) ; [CrossRef](#)
3. O'Connell, J. X., R. H. Young, et al. (1997). "Nodular fasciitis of the vulva: a study of six cases and literature review." *Int J Gynecol Pathol* 16(2): 117-123. [PubMed](#) ; [CrossRef](#)
4. Biedrzycki, O. J., N. Singh, et al. (2007). "Nodular fasciitis of the vulva with an unusually long clinical history; the importance of making this unexpected diagnosis in such an unusual site." *Histopathology* 51(4): 547-550. [PubMed](#) ; [CrossRef](#)
5. LiVolsi, V. A. and J. J. Brooks (1987). "Nodular fasciitis of the vulva: a report of two cases." *Obstet Gynecol* 69(3 Pt 2): 513-516. [PubMed](#)